

## MAMMARY BIOPSY IN INDUCED LACTATING GOATS: ASSESSMENT OF POST-BIOPSY MILK PROPERTIES AND ULTRASONOGRAPHIC APPEARANCE

### *BIÓPSIA MAMÁRIA DE CAPRINOS EM LACTAÇÃO INDUZIDA: AVALIAÇÃO DAS PROPRIEDADES DO LEITE E DA APARÊNCIA ULTRASSONOGRÁFICA APÓS BIÓPSIA*

Francisco Carlos de Sousa<sup>1</sup>  
Alexandre Rodrigues Paula Júnior<sup>2</sup>  
Iana Sales Campelo<sup>2</sup>  
Luciana Magalhães Melo<sup>2</sup>  
Vicente José de Figueirêdo Freitas<sup>2</sup>  
Dárcio Ítalo Alves Teixeira<sup>2\*</sup>

<sup>1</sup>Instituto Federal do Ceará, Crateús, CE, Brazil

<sup>2</sup>Universidade Estadual do Ceará, Fortaleza, CE, Brazil.

\*Author for correspondence - [darcio.teixeira@uece.br](mailto:darcio.teixeira@uece.br)

#### **Abstract**

The aim of this study was to evaluate the effects of mammary biopsy procedures on gland function of goats submitted to hormonal lactation. Ten female Caninde goats, at the age of around 3 years, were used, and lactation was induced by using estrogen, progesterone, and prednisolone. Ultrasonographic examinations of mammary gland, milking, and analysis of physicochemical properties of milk were performed immediately before (0 h) and 24, 48, and 72 h after each biopsy procedure. Surgical mammary gland biopsies were obtained at days 5 and 26 of the lactation. Even after drying initiation, all animals produced milk for five months. No abnormalities were observed on the ultrasonographic appearance of biopsied glands. All 20 biopsies were technically successful and any inflammation or infection was associated with biopsy procedures. Regarding the physicochemical properties and volumes of milk produced, no significant differences ( $P > 0.05$ ) were observed between right and left glands nor in the comparison of the results from time 0 with 24, 48, and 72 h for biopsied teats. The mammary biopsy did not induce neither severe changes in production and physicochemical properties of the milk nor in ultrasonographic appearance of mammary gland of goats in hormonal lactation.

**Keywords:** biopsy; goat; udder; ultrasonography.

#### **Resumo**

O objetivo deste estudo foi avaliar os efeitos dos procedimentos de biópsia mamária sobre a função da glândula de caprinos submetidos à lactação induzida. Dez cabras Canindé com idade de cerca de 3 anos foram utilizadas e a lactação foi induzida pelo uso de estrógeno, progesterona e prednisolona. Exames ultrassonográficos da glândula mamária, ordenha e análise das propriedades físico-químicas do leite foram realizados imediatamente antes (0 h) e 24, 48 e 72 h após cada procedimento de biópsia. As biópsias cirúrgicas de glândula mamária foram obtidas aos dias 5 e 26 da lactação. Mesmo após o início do processo de secagem, todos os animais continuaram produzindo leite por cinco meses. Nenhuma anormalidade foi observada na aparência ultrassonográfica das glândulas biopsiadas. Todas as 20 biópsias foram realizadas com sucesso e nenhuma inflamação ou infecção foi observada. Com relação às propriedades físico-químicas e volumes de leite produzido, nenhuma diferença significativa

( $P > 0,05$ ) foi observada entre a glândula direita e esquerda, nem comparando resultados do momento 0 com 24, 48 e 72 h para as glândulas biopsiadas. A biópsia mamária não induz severas mudanças na produção e nas propriedades físico-químicas do leite nem na aparência ultrassonográfica da glândula mamária de caprinos em lactação.

**Palavras-chave:** biópsia; caprino; úbere; ultrassonografia.

Received on: December 15<sup>th</sup>, 2015

Accepted on: August 4<sup>th</sup>, 2016

## Introduction

There is little information about mammary gland biopsy in goats. In spite of its reduced use for the diagnosis of mammary disorders, this procedure may be a tool to study the cellular proliferation and differentiation that occur during lactogenesis and help elucidate these processes. As examples, tissue samples obtained by surgical biopsy technique have been used for histological, histochemical, and ultra-structural studies of lactating mammary glands in goats<sup>(1,2)</sup>.

Procedures to induce animals into lactation may allow for the producer to retain animals in the producing herd that otherwise would be culled for any number of reasons, and for scientists, it may be a tool to study mammary biology during short-time periods of growth. The induction of lactation through hormonal stimulation has been previously demonstrated in goats<sup>(3-5)</sup>.

Although previous studies have employed the mammary biopsy in goats, any details relative to their effects on mammary physiology or possible complications were provided. Thus, the aim of this study was to evaluate the effects of mammary biopsy procedures on gland function of goats submitted to hormonal lactation. The evaluation was based on the assessment of pre- and post-biopsy milk production and physicochemical properties, as well as the ultrasonographic appearance of the mammary gland.

## Material and Methods

Goats females were submitted to hormonally induced lactation, hand-milked daily until D30 (beginning of milk production is on day 0 = D0), and thereafter at growing intervals until the lactation stopped. Ultrasonographic examinations of mammary gland, milking, and analysis of physicochemical properties of milk were performed immediately before (0 h), 24, 48, and 72 h after each biopsy procedure. Two mammary gland biopsies were performed in all does, firstly on the right gland (Biopsy 1) and after on the left gland (Biopsy 2), at 5 and 26 days of milk production, respectively.

All animal protocols used in this study were approved by the Animal Ethics Committee of the State University of Ceará (Protocol no. 12237085-6). Additionally, all studies were conducted according to the guidelines for the ethical use of animals in research<sup>(6)</sup>. Ten female Caninde goats at the age of around 3 years and weighing  $31.2 \pm 2.0$  kg (mean  $\pm$  standard error of the mean – SEM) were used. Animals received Tifton (*Cynodon dactylon*) hay in pens and were supplemented with commercial concentrate (20% crude protein). In addition, the does were housed indoors, had four hours of daily access to outside park and free access to water and mineralized salt.

All does were hormonally induced to lactate using the protocol earlier described by Cammuso et al.<sup>(3)</sup>. Briefly, estrogen (0.25 mg/kg, ECP, Pfizer, São Paulo, Brazil) and progesterone (0.75 mg/kg, Afisterone, Osasco, São Paulo, Brazil) were given on alternate days for a total of seven administrations. From day 14 of hormonal therapy, prednisolone (0.40 mg/kg, Corti-dural 20, Avellaneda, Argentina) was injected daily for three days.

The volume of milk produced was measured for each teat of individual female goats. Fresh milk samples were analyzed using Lactoscan SA Milk Analyser (Milkotronic Ltda., Nova Zagora, Bulgaria).

Physicochemical properties of milk such as fat (%), density, conductivity (mS/cm), solids-non-fat (%), proteins (%), pH, freezing point (°C), salts (%), and lactose (%) were recorded.

Ultrasound examinations were conducted using a convex array transducer of 5.0 MHz coupled to a B-mode Falco Vet 100 apparatus (Pie-Medical, Maastricht, Netherlands). Ultrasound configurations were not changed throughout the entire experiment for parameters such as over-all gain, far gain, near gain, and focus. Female goats were handled using gentle physical restraint and ultrasound gel was applied to the transducer and to their teat skin. The examination was performed in non-sedated does in standing position. The ultrasonographic technique used for mammary gland evaluation was in direct contact<sup>(7)</sup>. The transducer was placed on the caudal surface of the tested teat, in a vertical position, at an angle of approximately 30°, pointing to the gland cistern.

To reduce the time required for the examinations, all ultrasonographic procedures were recorded on video and analyzed retrospectively. Representative ultrasonograms in JPEG format were created from the videos using the program Gom Player (Gretech Corporation, Seoul, Korea), as described by Sousa et al.<sup>(8)</sup>. All examinations were performed by only one previously trained operator. The echogenicity of the mammary gland parenchyma and gland cistern were evaluated in ultrasonograms. Ultrasonographic measurements were performed using the software Image J 1.45s (National Institutes of Health, Millersville, USA).

Biopsies were performed in all does at both D5 (Biopsy 1) and D26 (Biopsy 2) of milk production, on the right and left mammary glands, respectively. Goats were denied access to feed 24 h and to water 12 h prior to the biopsy. This procedure was obtained from one-half of the udder – after milking – through a minor surgical procedure. The animals were anaesthetized using 0.1 mg/kg EV of xylazine hydrochloride at 2% (Kensol, Laboratórios König SA, Avellaneda, Argentina) combined with 5 mg/Kg ketamine hydrochloride at 10% (Quetamina, Vetecia Laboratório de Produtos Veterinários Ltda, Jacareí, Brazil). The does were restrained in dorsal recumbency, aseptically prepared and infiltrated with 1 mL intradermal of lidocaine at 2% (Lidovet, Laboratório Bravet Ltda, Rio de Janeiro, Brazil).

A small incision was made in the skin of the caudal surface of the teat and a piece of the parenchyma (0.5 cm<sup>3</sup>) was taken after dissection of the subcutaneous tissue and the gland capsule. The surgical wound was immediately closed with two separate sutures made of absorbable material. Animals were injected intramuscularly with antibiotic terramycin at 20 mg/kg (Terramicina/LA, Laboratórios Pfizer Ltda, Guarulhos, Brazil). The surgical wound was examined for the presence of possible inflammations or infections over a period of 60 days post-biopsy. Times to perform each procedure were recorded.

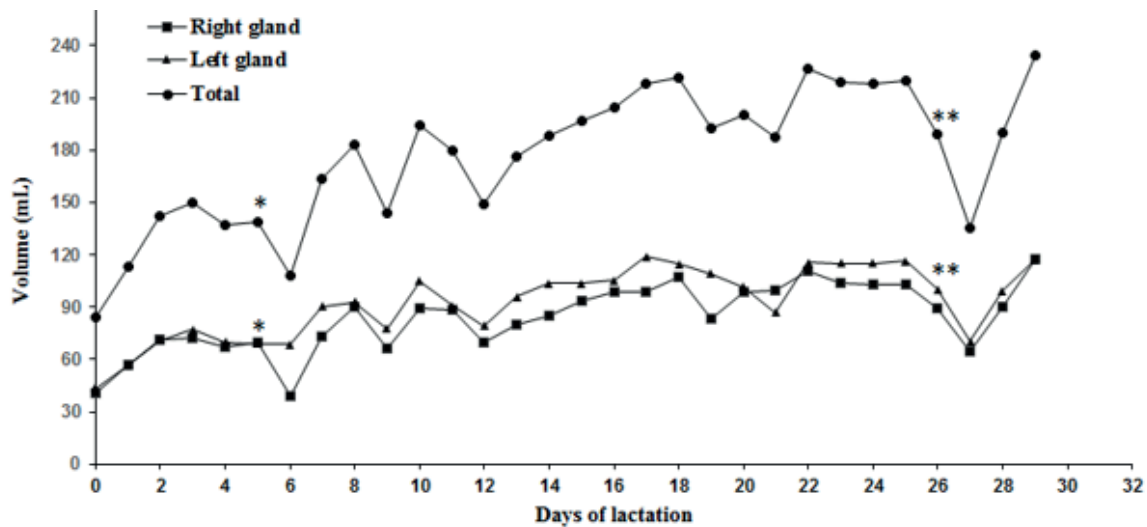
Values were expressed as mean ± standard deviation (SD) and differences were considered to be statistically significant at a level of  $P < 0.05$ . Statistical analyses were performed using GraphPad InStat 3.0 (GraphPad Software, San diego, USA). For data showing normal distribution, either paired or unpaired Student's *t* test, or Dunnett test was used as appropriate. For non-normally distributed data, Mann-Whitney-Wilcoxon test was used.

## Results and Discussion

All females responded to the treatment for induction of lactation in the first attempt and average milk volumes are presented in Figure 1. During the first 30 days of lactation, the daily average milk production (± SD) was  $177.4 \pm 140.9$  mL per doe. At the peak lactation, the daily average milk production (± SD) was  $234.4 \pm 180.9$  mL. In the 24 h after biopsy 2, one doe presented one clot in the milk, which disappeared one the day later.

The therapy used in the present study was effective to induce lactogenesis in all females. The successful lactation rate of 100% verified in this study was similar to the results obtained in other induced trials<sup>(9)</sup>. Furthermore, the lactation initiated in a similar period that has already been cited for goats<sup>(3)</sup>. The values of average daily milk production obtained on the first thirty days of lactation were

higher than those found by Batista et al.<sup>(5)</sup>, who also studied milk hormonally induced Caninde goats in the same lactation period.



**Figure 1:** Average milk production during hormonal lactation in goats. \*Biopsy 1. \*\*Biopsy 2.

The drying process was initiated five days after the second biopsy session. During the first and last month of the drying process, daily average milk production was  $116.7 \pm 76.7$  and  $21.7 \pm 13.4$  mL, respectively. Does stopped milk production after five months. Regarding the physicochemical properties and volumes of milk produced, no significant differences ( $P > 0.05$ ) were observed between right and left teats nor comparing results from time 0 with 24, 48, and 72 h for biopsied glands (Table 1).

Even after drying initiation, all animals produced milk for five months, showing that mammary biopsy did not affect the gland function. On the whole, the results pointed out to the complete absence of inflammations or infections of goat mammary glands. The milk composition was similar to that reported in an earlier experiment performed by our group with Caninde goats<sup>(5)</sup>. In addition, it is important to highlight that analysis of physicochemical properties and ultrasonographic examinations of mammary glands were relatively constant for all females throughout the lactation period. Finally, no alteration was observed in mammary gland inspection.

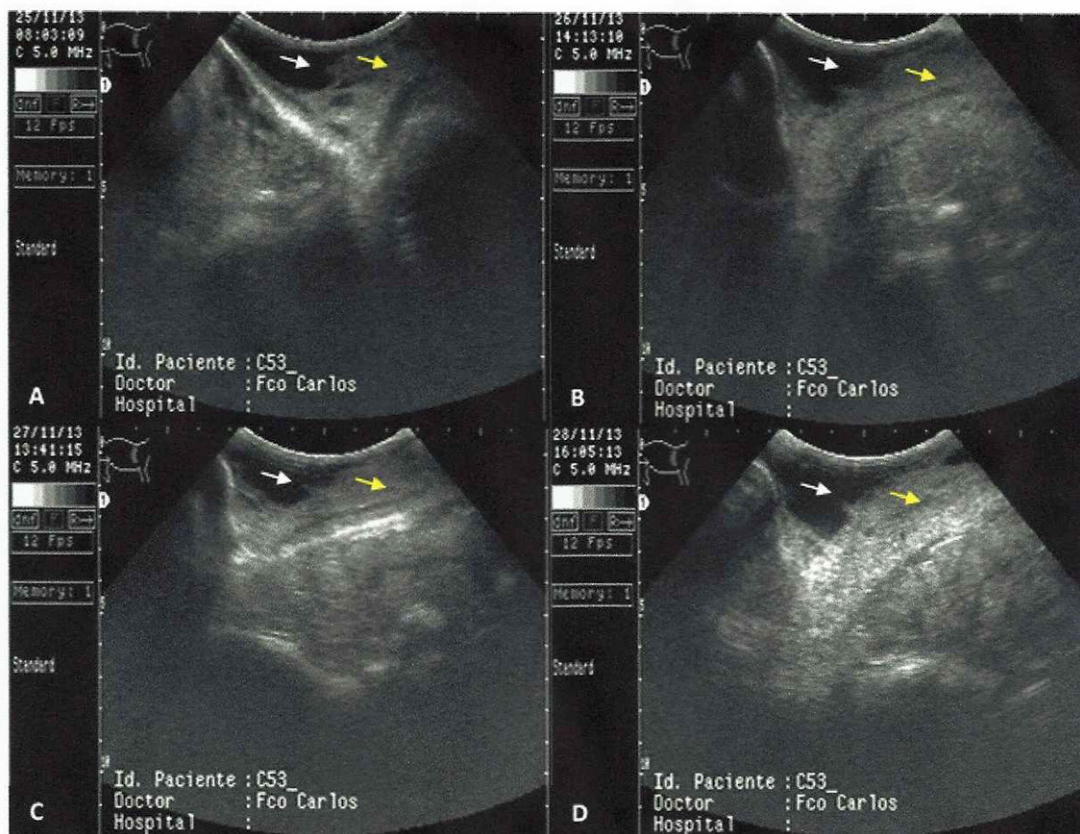
A total of 160 images of mammary glands were evaluated and in most exams, no abnormalities were observed on the ultrasonographic appearance of biopsied teats (Figure 2). In these cases, mammary glands exhibited a physiological sonographic appearance, demonstrating a parenchyma uniformly echogenic, with a granular echotexture. The milk secretion in the cistern led to an anechogenic image with echogenic particles. The large lactiferous ducts within the cisterns were clearly visible and anechogenic as well. Twenty-four hours after biopsy 2, one goat presented a 3.2 x 1.8 cm clot, located in the gland cistern of the left gland.

B-mode ultrasonography has been used to evaluate the mammary gland in cows<sup>(10)</sup> and goats<sup>(7)</sup>. According to Franz et al.<sup>(11)</sup>, ultrasonography of the udder parenchyma is a diagnostic aid in mastitis, enlargement of the udder without clinical signs of mastitis (eg. hematoma, neoplasia), and, occasionally, detection of penetrating foreign bodies. We report here the use of ultrasound technique to monitor the recovery process after surgical biopsy of mammary parenchyma. In the majority of the exams, the does showed a healthy mammary gland uniformly echogenic with a granular echotexture. This typical image was a result of connective tissue with higher and gland parenchyma with lesser echogenic density. Similar ultrasonographic appearance for lactating goat mammary gland was recently described by our group<sup>(7)</sup>.

**Table 1:** Yield and physicochemical properties of milk from Caprine goats during hormonal lactation after two biopsy procedures of mammary glands

Biopsy	Time (h)	Gland	Volume (mL)	Fat (%)	Solids-non-fat (%)	Protein (%)	Salts (%)	Lactose (%)	Density	pH	Freezing point (°C)	Conductivity (mS/cm)
1	0	Right	69.4±56.3	8.2±2.6	12.2±2.5	4.5±0.9	1.0±0.2	6.3±0.7	1041.3±8.0	5.5±0.2	-0.7±0.0	4.2±0.0
		Left	69.3±60.0	8.3±2.4	12.0±2.2	4.4±0.8	1.0±0.2	6.2±0.5	1040.3±7.0	5.5±0.1	-0.7±0.0	4.2±0.0
	24	Right	39.4±29.7	9.5±2.2	11.9±0.9	4.4±0.3	1.0±0.1	6.5±0.5	1039.1±2.9	6.3±0.2	-0.8±0.0	4.1±0.0
		Left	68.6±66.5	8.9±2.1	11.9±0.7	4.4±0.3	1.0±0.1	6.5±0.4	1039.8±1.8	6.3±0.2	-0.8±0.0	4.1±0.0
	48	Right	73.1±54.7	7.4±1.6	11.5±0.6	4.2±0.2	0.9±0.0	6.3±0.3	1039.1±1.7	6.4±0.2	-0.7±0.0	4.1±0.0
		Left	90.4±70.1	7.2±1.6	11.2±0.5	4.1±0.2	0.9±0.0	6.2±0.3	1038.3±1.8	6.4±0.1	-0.7±0.0	4.1±0.0
72	Right	90.3±62.4	6.8±1.0	11.3±0.5	4.2±0.2	0.9±0.0	6.2±0.2	1039.1±1.6	6.4±0.1	-0.7±0.0	4.1±0.0	
	Left	92.9±70.3	6.5±0.9	11.7±2.1	4.3±0.8	1.0±0.2	6.1±0.2	1038.3±1.6	6.5±0.2	-0.7±0.0	4.1±0.0	
2	0	Right	89.0±71.1	7.4±1.8	11.1±1.0	4.1±0.4	0.9±0.1	6.1±0.5	1037.6±3.1	6.5±0.1	-0.7±0.0	4.1±0.1
		Left	100.3±85.4	7.4±1.7	11.1±0.9	4.1±0.3	0.9±0.1	6.1±0.5	1037.5±2.5	6.5±0.1	-0.7±0.0	4.1±0.1
	24	Right	64.8±62.5	9.4±3.2	12.1±2.2	4.2±0.4	1.0±0.2	6.6±1.2	1038.1±3.1	6.5±0.1	-0.7±0.0	4.1±0.0
		Left	70.3±62.3	9.1±3.0	11.3±1.0	4.2±0.4	0.9±0.1	6.2±0.6	1037.2±2.2	6.5±0.1	-0.7±0.0	4.1±0.0
	48	Right	90.6±77.5	6.9±1.7	10.9±0.7	4.0±0.4	0.9±0.0	6.0±0.4	1037.4±2.5	6.6±0.2	-0.7±0.0	4.1±0.0
		Left	99.5±85.9	7.6±2.6	11.6±2.3	4.0±0.3	0.9±0.2	5.9±0.4	1036.9±2.2	6.6±0.3	-0.7±0.0	4.1±0.0
72	Right	117.3±92.5	5.7±1.5	10.7±0.5	3.9±0.2	0.9±0.0	5.9±0.3	1037.5±2.0	6.6±0.1	-0.7±0.0	4.1±0.0	
	Left	117.3±89.5	5.8±1.4	10.7±0.6	3.9±0.2	0.9±0.0	5.9±0.3	1037.3±2.1	6.6±0.1	-0.7±0.0	4.1±0.0	

All 20 biopsies were technically successful and any inflammation or infection was associated with biopsy procedures. The average times ( $\pm$  SD) to perform biopsies 1 and 2 were  $14.2 \pm 2.9$  (range, 10-16 min) and  $11.6 \pm 2.6$  min (range, 7-13 min), respectively. In the current study, biopsy was fast, safe, and minimally invasive, allowing to obtain mammary tissue sections in hormonally induced lactating goats. None of the biopsy procedures were associated with significantly decrease in milk yield.



**Figure 2:** Ultrasonography of goat mammary glands during hormonal lactation. Sonograms were recorded immediately before (A) and 24 (B), 48 (C) and 72 h (D) after biopsy of right gland 1. Gland cistern (white arrow) and gland parenchyma (yellow arrow).

## Conclusions

We concluded that mammary gland biopsy did not induce neither severe changes in production and physicochemical properties of the milk nor in ultrasonographic appearance of mammary gland of goats in hormonal lactation. Moreover, these results showed that mammary gland biopsy is a safe and efficient tool, which can be used to obtain tissue samples.

## Acknowledgments

The authors thank the staff of the Laboratory of Physiology and Control of Reproduction for technical assistance, Conselho Nacional de Desenvolvimento Científico e Tecnológico (CNPq, Brasília, Brazil), Coordenação de Aperfeiçoamento de Pessoal de Nível Superior (CAPES, Brasília, Brazil) and Fundação Cearense de Apoio ao Desenvolvimento Científico e Tecnológico (FUNCAP, Ceará, Brazil) that supported this work by supplying student and postdoc grants.

## Conflict of interest

The authors declare that they have no conflict of interest.

## References

1. El-Sayed EH, El-Shafie MH, Saifelnasr EOH, Abu El-Ella AA. Histological and histochemical study on mammary gland of Damascus goats through stages of lactation. *Small Rumin Res.* 2009;85:11-17. Available from: <<http://dx.doi.org/10.1016/j.smallrumres.2009.06.019>>.
2. El-Sayed EH, Hassan LR, Saifelnasr EOH, Ashmawy TAM. Ultra-structure study of mammary gland in Zairaibi goats during different stages of lactation. *Egypt J Sheep Goat Sci.* 2013;8:33-45. Available from: <<http://www.easg.eg.net/pdf/8-2-2013/4.pdf>>.
3. Cammuso C, Porter C, Nims S, Gaucher D, Melican D, Bombard S, Hawkins N, O'Coin A, Ricci C, Brayman C, Buzzell N, Ziomek C, Gavin W. Hormonal induced lactation in transgenic goats. *Anim Biotechnol.* 2000;1:1-17. Available from: <<http://www.tandfonline.com/doi/abs/10.1080/10495390009525943>>.
4. Moura RR, Albuquerque ES, Melo CHS, Alcântara Neto AS, Batista RITP, Nunes-Pinheiro DCS, Pereira AF, Teixeira DIA, Melo LM, Serova IA, Andreeva LE, Serov OL, Freitas VJF. Dynamics of recombinant hG-CSF in transgenic goat: preliminary study in the founder during hormonally induced lactation. *Anim Biotechnol.* 2013;24: 10-14. Available from: <<http://www.tandfonline.com/doi/full/10.1080/10495398.2012.729000>>.
5. Batista RITP, Melo CHS, Souza-Fabjan JMG, Teixeira DIA, Melo LM, Freitas VJF. Phenotypic features of first-generation transgenic goats for human granulocyte-colony stimulation factor production in milk. *Biotechnol Lett.* 2014;36:2155-2162. Available from: <<http://dx.doi.org/10.1007/s10529-014-1588-0>>.
6. ASAB. Guidelines for the treatment of animals in behavioral research and teaching. *Anim Behav.* 2012;71:245-253. Available from: <<http://dx.doi.org/10.1016/j.anbehav.2011.10.031>>.
7. Melo CHS, Sousa FC, Teles Filho ACA, Moura RR, Albuquerque ES, Pereira AF, Melo LM, Freitas VJF, Teixeira DÍA. Mensurações ultrassonográficas da cisterna da glândula mamária de caprino transgênico. *Arq Bras Med Vet Zootec.* 2012;64:491-494. Available from: <<http://dx.doi.org/10.1590/S0102-09352012000200033>>.
8. Sousa FC, Melo CHS, Teles Filho ACA, Avelar SRG, Moura AAA, Martins JAM, Freitas VJF, Teixeira DIA. Ovarian follicular response to different hormonal stimulation treatments in Canindé goats. *Anim Reprod Sci.* 2011;125:88-93. Available from: <<http://dx.doi.org/10.1016/j.anireprosci.2011.02.015>>.
9. Mellado M, Bernal A, Mendoza R, Carrillo E. Hormonal induction of lactation in prepuberal and multiparous crossbred goats kept under extensive conditions. *Small Rumin Res.* 1996;19:143-147. Available from: <[http://dx.doi.org/10.1016/0921-4488\(95\)00746-6](http://dx.doi.org/10.1016/0921-4488(95)00746-6)>.
10. Caja G, Ayadi M, Knight CH. Changes in cisternal compartment based on stage of lactation and time since milk ejection in the udder of dairy cows. *J. Dairy Sci.* 2004; 87: 2409-2415. Available from: <[http://dx.doi.org/10.3168/jds.S0022-0302\(04\)73363-9](http://dx.doi.org/10.3168/jds.S0022-0302(04)73363-9)>.
11. Franz S, Floek M, Hofmann-Parisot M. Ultrasonography of the bovine udder and teat. *VetClin N Am, Food AnimPract.* 2009;25:669-685. Available from: <<http://dx.doi.org/10.1016/j.cvfa.2009.07.007>>.