









HET-CAM assay for evaluation of eye drops based on pequi (*Caryocar brasiliense*) peel and pulp: a preliminary study

Ensaio HET-CAM para avaliação de colírio a base da casca e polpa de pequi (*Caryocar brasiliense*): estudo preliminar

João Marcelo Carvalho do Carmo¹ , Bárbara Elisa Basilio de Oliveira¹ , Nathany Arcaten¹ , Mariana Ferreira da Silva¹ , Cristielle Nunes Souto² , Mônica Rodrigues Ferreira Machado¹ , Andréia Vitor Couto do Amaral¹ 

¹ Universidade Federal de Jataí (UFJ), Jataí, Goiás, Brazil. 

² Universidade Federal Rural do Rio de Janeiro (UFRRJ), RJ, Rio de Janeiro, Brazil. 

*corresponding author: joaomarcelo_c2@hotmail.com

Received: May 19, 2024. Accepted: September 10, 2024. Published: March 27, 2025. Editor: Luiz Augusto B. Brito

Abstract: Ophthalmic disorders of infectious or inflammatory origin can often affect companion animals. In this context, research related to *Caryocar brasiliense* has shown benefits such as antibiotic, antioxidant, antifungal, and anti-inflammatory action, and it is expected to be beneficial for ophthalmopathy treatment. This research aimed to develop solutions of pequi peel and pulp extracts and then perform preclinical tests to assess the irritating potential using the HET-CAM test through the appearance of vascular lesions, simulating the ocular conjunctiva. For this purpose, 56 embryonated chicken eggs were subjected to solutions of ethanol extract of peel (EEP) and hexane extract of pulp (HEP) at concentrations of 0.1, 0.2, 0.25, 1.0, and 2.5% for eyedrops of peel (EPe) and 1.0, 1.5, 2.0, 10.0, and 20.0% for eyedrops of pulp (EPu), in addition to negative controls, consisting of Tween at 0.5 and 1.0% and NaCl. The positive control was performed with 0.1 N NaOH, and bleeding, hyperemia, and coagulation reactions were observed. The second-order polynomial was the regression model that best fitted the data, presenting the ideal value for EPu of 0.18% and EPe of 0.24%. The therapeutic benefits of *C. brasiliense* and the low potential for irritation of the tested solutions indicated a promising use for ophthalmopathies.

Keywords: alternative test; embryonated egg; ophthalmology; eye irritation.

Resumo: Afecções oftálmicas de origem infecciosa ou inflamatória podem frequentemente acometer animais de companhia. Neste sentido, pesquisas referentes ao *Caryocar brasiliense* vêm apresentando benefícios como ação antibiótica, antioxidante, antifúngica e anti-inflamatória e, diante disso, é esperado que possa ser benéfico para o tratamento de oftalmopatias. Objetivou-se nessa pesquisa desenvolver soluções dos extratos da casca e polpa do pequi e, em seguida, realizar testes pré-clínicos para avaliar o potencial irritante por meio do ensaio HET-CAM, por meio do aparecimento de lesões vasculares, simulando a conjuntiva ocular. Para isso, foram utilizados 56 ovos embrionados de galinha, submetidos a soluções do extrato etanólico da casca (EEC) e do extrato hexânico polpa (HEP), nas concentrações



denominadas colírio da casca (CC) e colírio da polpa (CP) a CC0,1%, CC0,2%, CC0,25%, CC1% e CC2,5% e CP1%, CP1,5%, CP2%, CP10% e CP20%, além dos controles negativos, utilizando Tween a 0,5% e 1% e NaCl. O controle positivo foi realizado com NaOH 0,1 N, onde reações de hemorragia, hiperemia e coagulação foram observadas. O modelo de regressão que melhor se ajustou aos dados foi o polinomial de segunda ordem, apresentando o valor ideal para CP de 0,18% e para CC de 0,24%. Os benefícios terapêuticos do *Caryocar brasiliense*, juntamente ao baixo potencial de irritação das soluções testadas, indicam um uso promissor para oftalmopatias.

Palavras-chave: teste alternativo; ovo embrionado; oftalmologia; irritação ocular.

1. Introduction

Pequi, the fruit of *Caryocar brasiliense*, is covered by a woody shell rich in fiber, carbohydrates, magnesium, calcium, and copper. It has up to four large seeds, with large, fleshy pits with sharp spines inside ⁽¹⁾. Its pulp is composed of unsaturated fatty acids, such as linoleic acid ⁽²⁾, which plays an important role in the healing process, increasing collagen synthesis and providing the tissue with higher tensile strength ⁽³⁾, in addition to attenuating the inflammatory process during the tissue repair period ⁽⁴⁾.

It is also rich in carotenoids such as antheraxanthin, cryptoflavin, zeaxanthin, β -cryptoxanthin, ζ -carotene, β -carotene, and mutatoxanthin, which have antioxidant action, in addition to being precursors of vitamin A ⁽⁵⁾, known to regulate the differentiation and proliferation of corneal epithelial cells, also acting in the preservation of goblet cells of the conjunctiva. For this reason, it has been used to treat ophthalmic diseases such as keratoconjunctivitis sicca ^(6,7). No studies on the effects of the extract of peel or pulp of *C. brasiliense* on the ocular surface have been found. However, an in vitro study indicated that the alcohol extract of peel has antimicrobial potential against methicillin-resistant *Staphylococcus pseudintermedius* isolated from the ocular surface of dogs with ophthalmopathies ⁽⁸⁾.

The treatment of these ophthalmic conditions is usually performed using topical and systemic medications. However, the latter route presents difficulties in the perfusion of drugs into the ocular tissues due to biological barriers, thus requiring higher doses that can cause systemic and ocular adverse effects ⁽⁹⁾. There has been an increasing search for natural active ingredients to reduce the side effects caused by synthetic medications ⁽¹⁰⁾. Toxicological tests are required for these active ingredients to be used as ophthalmic solutions, as the external structures of the eye, such as the cornea, conjunctiva, and iris, are delicate and may suffer chemical damage from the active ingredients and excipients present in ophthalmic solutions ⁽¹¹⁾.

The ocular irritation test generally used is the Draize test, which consists of instilling test substances on the eye surface of albino rabbits in a single dose, aiming to observe the degree of irritation and inflammation ⁽¹²⁾. However, alternative in vitro methods have been sought due to the suffering that animal models are subjected to, and the concept of the 3 Rs (reduce, replace, and refine) has been followed for the use of animals as experimental models, seeking to obtain the same parameters *in vivo* ^(13,14). In Brazil, using animals in research to develop hygiene products, cosmetics, and perfumes is currently prohibited ⁽¹⁵⁾.

The hen's egg test–chorioallantoic membrane (HET-CAM) stands out among the alternative ocular irritation methods, allowing an assessment of the irritant potential through vascular lesions, simulating the ocular conjunctiva^(16,17,18).

Considering the medicinal benefits of the properties of *C. brasiliense*, with anti-inflammatory, antimicrobial, and proliferative actions of corneal cells, the compounds are expected to be promising as adjuvants in the form of eye drops in treating eye diseases in companion animals. This research aims to formulate solutions of pequi pulp and peel in different concentrations for future ophthalmic use, starting the necessary preclinical tests using the HET-CAM test to identify ideal concentrations that cause no irritation.

2. Material and methods

2.1 Extract acquisition

The fruits of *C. brasiliense* were purchased fresh from a local store in the city of Jataí, Goiás, harvested from a single lot, coming from a rural perimeter, and sent to the Laboratory of Chemistry of the Federal University of Jataí (UFJ). Peels and pulps were separated and sliced, and each plant material underwent the addition of organic solvent according to its polarity, consisting of 92.8% alcohol for the peel and hexane for the pulp. The different parts of *C. brasiliense* remained in percolation for 7 days after the addition of the solvents, with the volume of solvent evaporating and subsequently replenished during this period. Then, the solvents were separated in a rotary evaporator and the extracts resulting from the separation were kept in a water bath until they reached constant weight, ensuring the total elimination of solvents from the medium.

The hexane extract of pulp (HEP) was fractionated into different concentrations called eyedrops of pulp (EPu) at concentrations of 1.0, 1.5, and 2.0%, diluted in Tween 80 (Tween 80, Labsynth) at 0.5%. EPu at concentrations of 10.0 and 20.0% diluted in 1.0% Tween were also formulated. The concentrations of 0.5 and 1.0% were obtained using Tween 80 diluted in saline solution (0.9% NaCl saline solution 250 mL, Medflex), homogenized by vortexing for 15 minutes at room temperature. The ethanolic extract of peel (EEP) was divided into five concentrations, called eyedrops of peel (EPe): 0.1, 0.2, 0.25, 1.0, and 2.5%, diluted in saline solution (0.9% NaCl), after vortexing for 15 minutes.

The peel solutions were diluted in 0.9% sodium chloride to mimic future eyedrops, given its osmolarity (290 mOsm), close to that of dog tear fluid (337.4 ± 16.2 mOsm)⁽¹⁹⁾. The pH of the solutions was readjusted to 7.2 by adding hydrochloric acid (when necessary to reduce the pH) or sodium hydroxide (when necessary to increase the pH) to neutralize it, as these substances are used in commercial eyedrops, keeping it close to pH 7.0, the average pH of dog tear fluid⁽²⁰⁾.

2.2 Experimental trial

The study was approved by the Ethics Committee on the Use of Animals (CEUA) under No. 013/19. Fifty-six fertilized two-day-old Cobb chicken eggs, obtained from 34- to 35-day-old hens and donated by the company São Salvador Alimentos (Itaberaí, Goiás, Brazil), were used for the tests. The eggs were maintained at a controlled room temperature of 24 °C for 24 hours in a dark and silent room. Subsequently, the eggs were placed in an RcomPR50 digital incubator, with a temperature of 37.5 °C and humidity between 50 and 60%. The automatic rotation function was programmed to roll every 60 minutes until the eighth day of incubation and interrupted on the ninth day for the HET-CAM test. During this period, the conditions required for incubation mentioned above were monitored daily and adjusted as necessary, with embryo viability monitored by candling.

The HET-CAM test was performed according to the protocol by Luepke and Kemper ⁽¹⁶⁾ on the ninth day of incubation using embryonated chicken eggs randomly distributed into 14 groups of four eggs. Each group was tested with different solutions, that is, eyedrops of pulp (EPu) at EPu1.0%, EPu1.5%, EPu2.0%, EPu10.0%, and EPu20.0% and eyedrops of peel (EPe) at EPe0.1%, EPe0.2%, EPe0.25%, EPe1.0%, and EPe2.5%, diluted in saline solution. Two concentrations of polysorbate 80 at 0.5% (NC0.5%) and 1% (NC1%) and NaCl (NC0.9%) were used as negative controls. In addition, 0.1 N NaOH (PCNaOH) was used as a positive control.

Each egg was carefully cleaned with saline solution heated to 37 °C when removed from the incubator, followed by piercing the shell with a lanceolate needle and removal by anatomical forceps in the air chamber region until the CAM was exposed. The eggs were randomly selected for each group, receiving 0.2 ml of the solution corresponding to the selected group, carefully instilled onto the CAM by a pipette. The membrane was exposed to the test substance for 20 seconds, and then 10 ml of saline solution heated to 25 °C was instilled to remove the instilled solution. Subsequently, the absence and presence of subsequent irritation phenomena were observed and recorded for a total of five minutes from the instillation of the test solution.

All events were filmed using an Apple iPhone 12 digital device, allowing the observation and review of the presence or absence of the following phenomena: hyperemia (increased blood flow), hemorrhage (extravasation of blood from blood vessels), and coagulation (CAM opacity or coagulation in the vessels). Each embryonated egg was immediately euthanized by rapid cooling to -20 °C at the end of each test. The assessment of the irritant potential was based on the appearance of irritation phenomena at intervals of 0.5, 2, and 5 minutes ⁽¹⁶⁾.

2.3 Data analysis

The phenomena of hyperemia (Hyp), hemorrhage (Hem), and coagulation (Coag) were recorded when present. Each concentration, as well as the controls, were analyzed in quadruplicate. The time of the events was recorded in minutes, as shown in Table 1. A single numerical value was obtained to calculate the irritation score (mean score, MSc), allowing the observation of the irritation capacity of the tested solution on a common scale ranging from

0 to 21 (Table 2). Linear and quadratic regression models were tested using GraphPad Prism 6 software. The quadratic regression model was expressed by the following equation:

$$Y = \beta_0 + \beta_1 X + \beta_2 X^2 + \epsilon$$

where Y is the dependent variable, X is the independent variable, β_0 , β_1 , and β_2 are the coefficients of the model, X^2 is the quadratic term, which captures the curvature of the relationship, and ϵ is the error term, which represents the variation not explained by the model.

The linear regression model was described by the equation:

$$Y = \beta_0 + \beta_1 X + \epsilon$$

where Y is the dependent variable, X is the independent variable, β_0 is the intercept, or constant, which represents the expected value of Y when $X = 0$, β_1 is the regression coefficient for X, which represents the expected change in Y for each unit of change in X.

Table 1. Scores of the lesions shown in the CAM during the evaluation (hyperemia, hemorrhage, and coagulation), according to the time of appearance (0.5, 2, and 5 minutes), according to Luepk and kemper⁽¹⁷⁾.

| Effect | Score | | |
|-------------|---------------|---------------|---------------|
| | 0.5 min (30s) | 2 min (120 s) | 5 min (300 s) |
| Hyperemia | 5 | 3 | 1 |
| Hemorrhage | 7 | 5 | 3 |
| Coagulation | 9 | 7 | 5 |

Table 2. Category of irritation according to the score range obtained from the mean score of each group, according to Luepk and kemper⁽¹⁷⁾.

| Score range | Category of irritation |
|-------------|------------------------|
| 0 to 0.9 | No irritation |
| 1 to 4.9 | Mild irritation |
| 5 to 8.9 | Moderate irritation |
| 9 to 21 | Severe irritation |

3. Results

The E_{Pu} concentrations presented a citrine yellow color, slightly turbid, requiring vortexing for 15 minutes for homogenization. However, a slight separation of phases was still observed, with the most yellowish color as the supernatant, but it became homogeneous with manual stirring, without the presence of odor. The E_{Pe} concentrations presented a very

light amber color without supernatant or decantation and odorless after vortexing for 15 minutes for homogenization. The pH of all solutions was adjusted to 7.2, seeking proximity to the tear pH.

The PCNaOH group showed changes in hemorrhage and hyperemia immediately after the NaOH solution instillation in all eggs and coagulation in only one egg. These changes persisted throughout the test period, obtaining a score of 14.25, classified as a severe irritation. The NC0.5% showed hyperemia in only one egg at 5 minutes and NC1.0% presented hemorrhage at 5 minutes, reaching scores of 0.25 and 0.75, respectively, with both concentrations of Tween 80 used to dilute the EPU classified as non-irritating.

The EPe concentrations caused hyperemia in the CAM after 2 minutes of the instillation with EPe0.1%, EPe0.2%, and EPe0.25% in two, one, and three eggs, respectively, with scores ranging from 0 to 0.9 on the HET-CAM scale, considered as non-irritating. EPe1.0% caused hyperemia at 2 minutes in one egg and at five minutes in another, scoring 1 on the HET-CAM scale. After the instillation of EPe2.5%, hemorrhage was observed only at 5 minutes in two eggs, scoring 1.5 on the HET-CAM scale, both considered mild irritants.

In the EPU groups, CAM presented hyperemia after two minutes with the instillation of EPU1.0% in two eggs, EPU1.5% in one egg, and EPU2.5% in two eggs, with scores ranging from 0 to 0.9 on the HET-CAM scale, considered non-irritating. The instillation of EPU10.0% caused hyperemia after two minutes in one egg, as well as hemorrhage, followed by hyperemia after five minutes in another egg, scoring 2.25 on the HET-CAM scale. EPU20.0% showed the coagulation phenomenon after two minutes in only one egg, and hemorrhage after two minutes in two other eggs, scoring 4.2 on the HET-CAM scale, leading to mild irritations at these concentrations (Table 3).

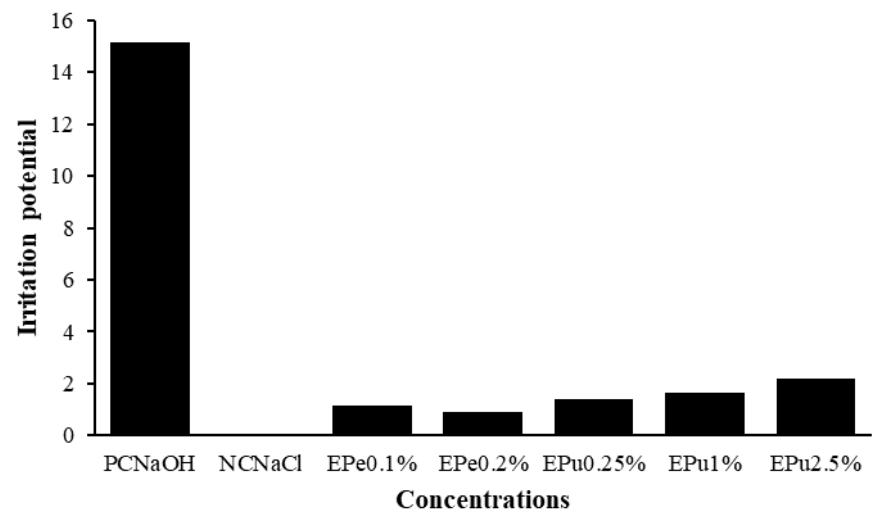
Table 3. Different concentrations of *C. brasiliense* peel and pulp tested in the experiment with their respective irritation scores and classification of the degree of irritation according to the HET-CAM.

| Solution | Irritation score (MSc) | Classification |
|----------|------------------------|----------------|
| PCNaOH | 14.25 | SI |
| NC0.5% | 0.25 | NI |
| NC1.0% | 0.75 | NI |
| NC0.9% | 0 | NI |
| EPU1.0% | 0.5 | NI |
| EPU1.5% | 0.25 | NI |
| EPU2.0% | 0.5 | NI |
| EPU10.0% | 2.25 | MI |
| EPU20.0% | 4.25 | MI |
| EPE0.1% | 0.5 | NI |
| EPE0.2% | 0.25 | NI |
| EPE0.5% | 0.75 | NI |
| EPE1.0% | 1 | MI |
| EPE2.5% | 1.5 | MI |

PC: positive control; NC0.5%: negative control at 0.5% Tween; NC1.0%: negative control at 0.5% Tween; EPU: eyedrops of pulp; EPE: eyedrops of peel; NI: no irritation; MI: mild irritation; SI: severe irritation.

The results show that the higher the concentration, the higher its irritant potential (Figures 1 and 2).

Figure 1. Irritant potential of different concentrations of eyedrops of peel (EPe) from *C. brasiliense*,



negative control NaCl (NC0.9%), and positive control (NaOH) PCNaOH.

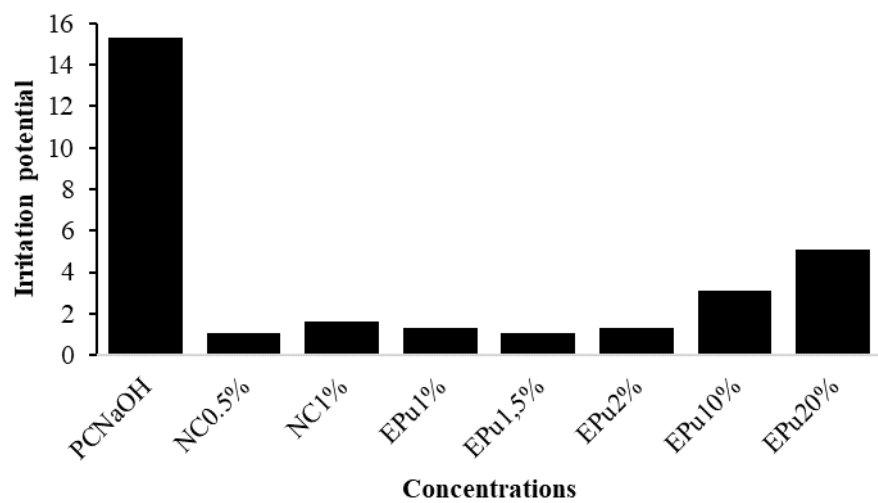


Figure 2. Irritant potential of different concentrations of eyedrops of pulp (EPu) from *C. brasiliense*, and negative controls NC1.0% (Tween 1.0%) and NC0.5% (Tween 0.5%), and positive control (NaOH) PCNaOH.

Figure 3 shows the results in images of eggs from the negative and positive control groups, with the absence or presence of irritation phenomena, photographed at 5 minutes (Fig. 3).

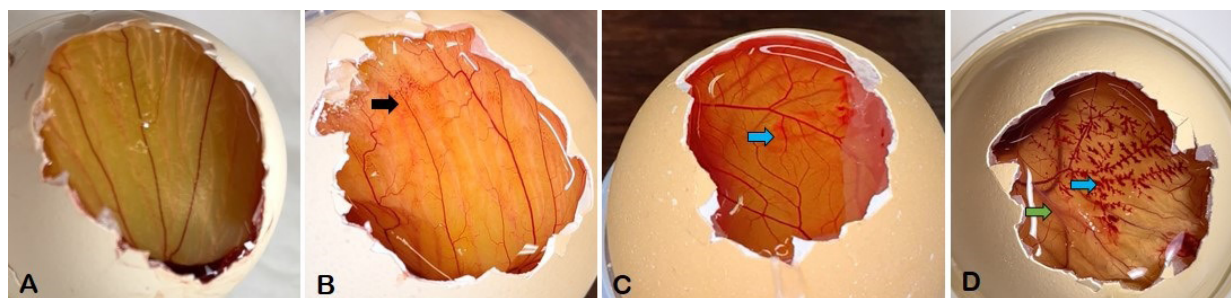


Figure 3. A: Egg from the group treated with NC0.9% without irritation changes. B: Egg from the group treated with NC0.5%, showing hyperemia in the black arrow. C: Egg from the group treated with NC1.0%, showing hemorrhage in the blue arrow. D: Egg from the group treated with PCNaOH, showing hemorrhage in the blue arrow and coagulation in the green arrow (thrombus in the blood vessel).

Figure 4 shows the results in images of eggs treated with HEP and EE at different concentrations, with the irritation phenomena, photographed at 5 minutes (Fig. 4).

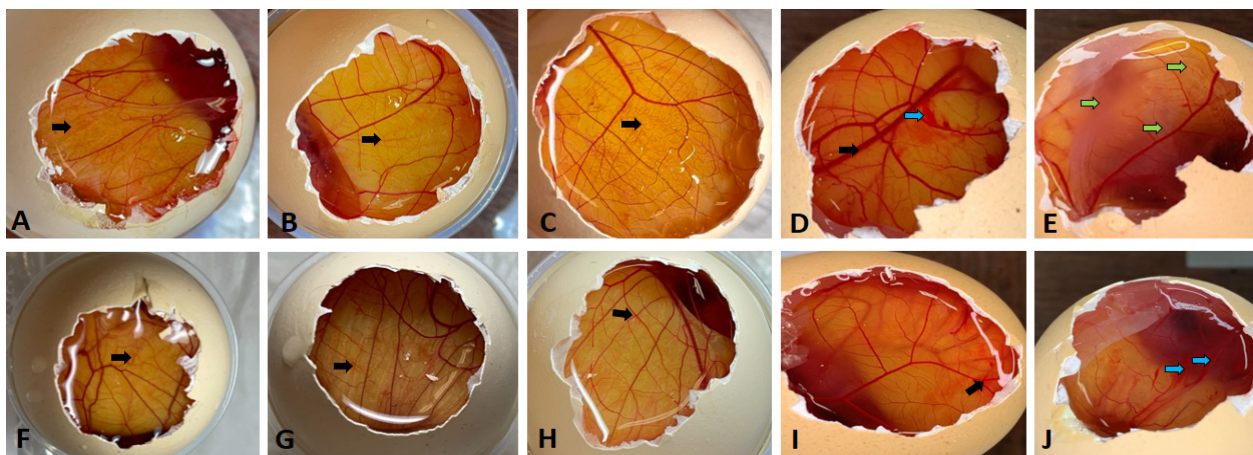


Figure 4. A: Egg from the group treated with EPU1.0%, showing hyperemia in the black arrow. B: Egg from the group treated with EPU1.5%, showing hyperemia in the black arrow. C: Egg from the group treated with EPU2.0%, showing hyperemia in black arrow. D: Egg from the group treated with EPU10.0%, showing hemorrhage in the blue arrow and hyperemia in the black arrow. E: Egg from the group treated with EPU20.0%, showing coagulation in the green arrow. F: Egg from the group treated with EPE0.1%, showing hyperemia in the black arrow. G: Egg from the group treated with EPE0.2%, showing hyperemia in the black arrow. H: Egg from the group treated with EPE0.25%, showing hyperemia in the black arrow. I: Egg from the group treated with EPE1.0%, showing hyperemia in the black arrow. J: Egg from the group treated with EPE2.5%, showing hemorrhage in the blue arrow.

The second-order polynomial regression model best fitted the dose with the lowest irritation potential, represented by the equation $Y = 0.09739 + 0.2178x - 0.0004972x^2$, with an $R^2 = 0.9944$ and $X = 0.18$ for EPU and $Y = 0.3612 + 0.7720x - 0.1267x^2$, with an $R^2 = 0.8774$ and $X = 0.24$ for EPE. The linear model presented the equation $Y = 0.2077x + 0.1172$ and $R^2 = 0.9942$ for EPU and the equation $Y = 0.4403x + 0.4433$ and $R^2 = 0.8557$ for EPE (Fig. 5).

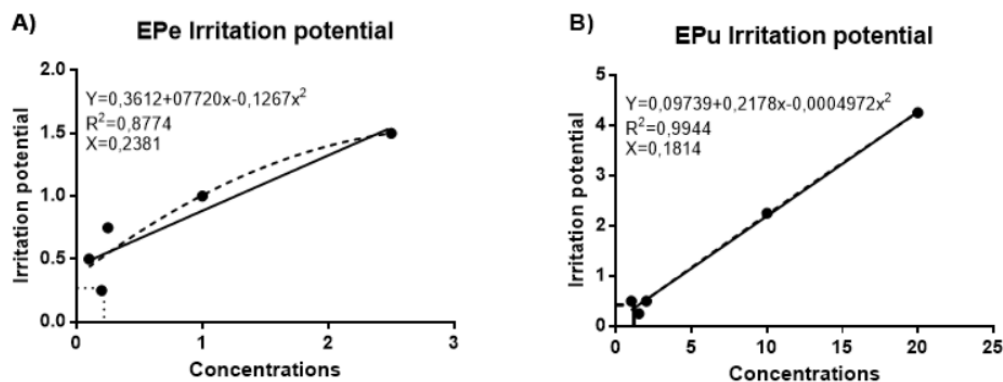


Figure 5. Irritant potential of embryonated chicken eggs tested with eyedrops of peel (EPe) (A) and eyedrops of pulp (EPu) (B). Dashed lines demonstrate the behavior of the quadratic model and the continuous line the behavior of the linear model. The independent variable (X) is the administered dose, while the dependent variable (Y) is the observed response.

4. Discussion

The main constituents of the *C. brasiliense* extract are described in the literature as chemical compounds with antimicrobial action, such as flavonoids and terpenoids. Flavonoids can interact with the cytoplasmic membrane, inhibiting its function and compromising cellular integrity, and can also inhibit the synthesis of nucleic acids, interrupting bacterial metabolism ⁽²¹⁾. In contrast, terpenoids have lipophilic characteristics that affect the stability of the cytoplasmic membrane of bacteria, leading to the loss of enzymes and cellular nutrients ⁽²²⁾.

The antibiotic components in the *C. brasiliense* extract have significant therapeutic potential, especially at concentrations of EPe1.0% and EPe2.5%, doses considerably higher than those used in the present investigation. These concentrations may be effective in the management of bacterial ophthalmic diseases in companion animals, including ulcerative keratitis, uveitis, and keratoconjunctivitis sicca. The literature supports this hypothesis. Previous studies have shown that 2.2% *C. brasiliense* peel extract exhibits substantial antibiotic activity against methicillin-resistant *Staphylococcus* spp., a strain isolated from the eye surface of dogs with these ophthalmopathies ⁽⁸⁾. In contrast, the mentioned study found that the pulp extract showed no antibiotic activity against the same bacteria at concentrations below 25%. This finding suggests that the pulp extract at the concentrations used in this study may not provide the desired efficacy for therapeutic purposes. Consequently, these results highlight the importance of carefully selecting the concentrations and components of *C. brasiliense* extract to optimize therapeutic efficacy against resistant bacterial strains, which may have important implications for veterinary medicine and the development of new treatment strategies.

No studies on topical toxicity with the use of pequi extracts have been found in the literature. Therefore, the tested substances were diluted at lower concentrations, considering the high presence of tannins and flavonoids, xenobiotic substances that can produce toxic

metabolites in the body ⁽²³⁾. For this purpose, HEP was diluted in Tween 80, acting as a demulcent to facilitate the solubility of lipid components ⁽²⁴⁾ which in turn was previously diluted in 0.9% sodium chloride (NaCl). EE was also diluted in NaCl and used as a diluent aiming to mimic a veterinary eyedrop, considering that its osmolarity (290 mOsm) is close to that of dog tear fluid (337.4 ± 16.2 mOsm) ⁽¹⁹⁾. The vehicles (Tween and NaCl) were safe, as they were tested in negative control groups and were classified as non-irritating to HET-CAM in the present study.

To avoid irritations, buffer excipients commonly used in eyedrop formulations were used to neutralize the pH to 7.2, namely hydrochloric acid (when a decrease in pH is necessary) or sodium hydroxide (when an increase in pH is necessary), considering that the pH of tears in dogs can vary between 6.0 and 8.0, with an average of 7.0 ⁽²⁰⁾.

The appearance of vascular phenomena in the groups tested with EPu10.0%, EPu20.0%, EPe1.0%, and EPe2.5%, classified as concentrations that have the potential to irritate the eyes, does not rule out the use of these substances *in vivo*, as they can still be verified using other tests, such as CAM-TBS (chorioallantoic membrane – trypan blue staining), which has the initial methodology of HET-CAM but has trypan blue applied after instillation of the test substance, it allows the evaluation of damage to CAM through the amount of dye absorbed, allowing the identification of false positives in HET-CAM, as it tends to overestimate vascular reactions ⁽¹⁷⁾. However, the non-irritating concentrations tested in this study will not need to be tested in animals, as they will present effects similar to those of HET-CAM, not generating irritation *in vivo*.

The HET-CAM irritation test showed that the solutions with lower concentrations presented lower irritant potential, indicating a relationship between concentration and irritant potential, which can be observed in tests with other plant extracts. An example is the study carried out with *Cantua buxifolia* Juss., which presented a non-irritant category on the HET-CAM scale at concentrations of 0.1, 0.2, and 0.3% ⁽²⁵⁾. Even though there is a lack of studies using *C. brasiliense* for ophthalmic treatments, the use of phytotherapeutics in ophthalmology has proven to be prosperous. Solutions from *Citrus limon* ⁽²⁶⁾, *Copaifera multijuga* ⁽²⁷⁾, *Aloe vera* ⁽²⁸⁾ and *Ottonia martiana* ⁽²⁹⁾ have already been tested for use in the treatment of ophthalmopathies, showing promising results and proving that the therapeutic use of plants in ophthalmology can be beneficial.

Regression models have been employed in dose-response trials for drug use ⁽³⁰⁾. According to the model that presented the best fit (second-order polynomial model), the doses with the lowest irritation potential were 0.18% for HEP and 0.23% for EE. A regression model is a powerful statistical tool for analyzing dose-response trials, where the relationship between different doses of a product (such as a drug or a nutrient) and the response observed in an organism is evaluated. This study deals with a dose-response trial, whose objective is to understand how different doses of the evaluated products affected the irritation potential ⁽³¹⁾.

The relationship between the dose and the response is not always linear in a dose-response trial. An initial increase in the dose may lead to a proportional increase in the response up to a certain point, after which the response may stabilize or even decrease, indicating a more complex relationship⁽³²⁾, as observed in this study.

5. Conclusion

The concentrations of 0.18% and 0.24% indicate low irritant potential for eyedrops of pulp and eyedrops of peel solutions, respectively. This study paves the way for *in vivo* research on the ophthalmic use of *C. brasiliense* extracts with these concentrations in animals with ophthalmopathies, adding medicinal value to this species and promoting the use of peel residues, reducing its environmental impact.

Supplementary material

[Graphical Abstract](#) (only available in the electronic version).

Conflict of interest statement

The authors declare no conflict of interest.

Data availability statement

The data will be provided upon request.

Author contributions

Conceptualization: J. M. C. do Carmo, C. N. Souto and A. V. C. do Amaral; *Data curation:* J. M. C. do Carmo, C. N. Souto, M. R. F. Machado and A. V. C. do Amaral; *Formal analysis:* J. M. C. do Carmo; *Methodology:* J. M. C. do Carmo, M. F. da Silva, B. E. B. de Oliveira and N. Arcaten; *Investigation:* J. M. C. do Carmo, C. N. Souto, M. F. da Silva, B. E. B. de Oliveira, N. Arcaten and A. V. C. do Amaral; *Validation:* A. V. C. do Amaral; *Supervision:* A. V. C. do Amaral; *Resources:* A. V. C. do Amaral; *Project administration:* A. V. C. do Amaral; *Funding acquisition:* A. V. C. do Amaral; *Written by:* J. M. C. do Carmo, C. N. Souto, M. R. F. Machado and A. V. C. do Amaral.

References

1. Lorenzi, H. Árvores brasileiras: Manual de identificação e cultivo de plantas arbóreas nativas do Brasil. Nova Odessa: Plantarum. 1992 273p.
2. Lima A de, Silva AM de O e, Trindade RA, Torres RP, Mancini-Filho J. Composição química e compostos bioativos presentes na polpa e na amêndoa do pequi (*Caryocar brasiliense*, Camb.). Revista Brasileira de Fruticultura. 2007; 29(3):695–8. <https://doi.org/10.1590/S0100-29452007000300052>
3. Nascimento WM, Maia Filho ALM, Costa CLS da, Martins M, Araújo KS de. Estudo da resistência cicatricial cutânea de ratos tratados com óleo de pequi (*Caryocar brasiliense*). ConScientiae Saúde. 2016 Jan 21;14(3):449–55. <https://doi.org/10.5585/conssaude.v14n3.5467>
4. Batista JS, Silva AE, Rodrigues CMF, Costa KMFM, Oliveira AF, Paiva ES, et al. Avaliação Da Atividade Cicatrizante Do Óleo De Pequi (*Caryocar coriaceum* Wittm) Em Feridas Cutâneas Produzidas Experimentalmente Em Ratos. Arquivos do Instituto Biológico. 2010 Set;77(3):441–7. <https://doi.org/10.1590/1808-1657v77p4412010>
5. Ramos M.I.L., Umaki M.C.S., Hiane P.A., Ramos F. M. M. Efeito do cozimento convencional sobre os carotenóides pró-vitâmicos “A” da polpa do pequi (*Caryocar brasiliense* Camb). Boletim do Centro de Pesquisa de Processamento de Alimentos. 2023; 19(1). Disponível em: <https://revistas.ufpr.br/alimentos/article/view/1219/1019>
6. Selek H, Ünlü N, Orhan M, Irkeç M. Evaluation of Retinoic Acid Ophthalmic Emulsion in Dry Eye. European Journal of Ophthalmology. 2000 Abril; 10(2):121–7. <https://doi.org/10.1177/112067210001000205>

7. Ohashi Y, Watanabe H, Kinoshita S, Hosotani H, Umemoto M, Manabe R. Vitamin A Eyedrops for Superior Limbic Keratoconjunctivitis. *American Journal of Ophthalmology*. 1988 Mai;105(5):523–7. [https://doi.org/10.1016/0002-9394\(88\)90245-0](https://doi.org/10.1016/0002-9394(88)90245-0)
8. Bruno-Filho FF, Ataíde WF, Stella AE, Benite-Ribeiro SA, Nebo L, Amaral AVC. Inhibition potential of *Caryocar brasiliense* on methicillin-resistant *Staphylococcus pseudintermedius* isolated from the ocular surface of dogs with ophthalmopathies. *Arquivo Brasileiro de Medicina Veterinária e Zootecnia*. 2023; 75(1):41–7. <http://dx.doi.org/10.1590/1678-4162-12593>
9. Figueira L, Torção L, Dinis SA, Palmares J. Antibioterapia ocular. Segunda ed. Porto: Medesign. 2010, 151 p.
10. González JY. Uso tradicional de plantas medicinales em la Vereda San Isidro, Municipio de San José de Pare Boyacá: um estudio preliminar usando tecnicas quantitativas. *Acta Biológica Colombiana*. 2006; 11(1):1-10. Disponível em: http://www.scielo.org.co/scielo.php?script=sci_arttext&pid=S0120-548X2006000200012&lng=en&nrm=iso
11. Abdelkader H, Pierscionek B, Carew M, Wu Z, Alany RG. Critical appraisal of alternative irritation models: three decades of testing ophthalmic pharmaceuticals. *British Medical Bulletin*. 2015 Fev 16;113(1):59–71. <https://doi.org/10.1093/bmb/ldv002>
12. Test No. 405: Acute Eye Irritation/Corrosion. OECD Guidelines for the Testing of Chemicals, Section 4. OECD; 2021. <https://doi.org/10.1787/9789264185333-en>
13. Oliveira, A. G. L. et al. Ensaios da membrana cório-alantoide (HET-CAM e CAM-TBS): alternativas para a avaliação toxicológica de produtos com baixo potencial de irritação ocular. *Revista do Instituto Adolfo Lutz, São Paulo*, v. 71, n. 1, p. 153-159, 2012. <https://www.arca.fiocruz.br/handle/icict/8985>
14. Eskes C, Bessou S, Bruner L, Curren R, Harbell J, Jones P, et al. Eye irritation. *Alternative Laboratory Animal*. 2005 jul; 33 (1): 47–81. <https://doi.org/10.1177/026119290503301s09>
15. Brasil. Resolução Nº 58, De 24 De Fevereiro De 2023. Dispõe sobre a proibição do uso de animais vertebrados, exceto seres humanos, em pesquisa científica, desenvolvimento e controle de produtos de higiene pessoal, cosméticos e perfumes que utilizem em suas formulações ingredientes ou compostos com segurança e eficácia já comprovadas cientificamente e dá outras providências. *Diário Oficial da União: Sessão 1, Brasília, DF, ed. 41, p. 8, 01 de mar. 2023*.
16. Luepke NP. Hen's egg chorioallantoic membrane test for irritation potential. *Food and Chemical Toxicology [Internet]*. 1985 feb; 23(2):287–91. [https://doi.org/10.1016/0278-6915\(85\)90030-4](https://doi.org/10.1016/0278-6915(85)90030-4)
17. Luepke NP, Kemper FH. The HET-CAM test: An alternative to the draize eye test. *Food and Chemical Toxicology*. 1986 Jun; 24(6-7):495–6. [https://doi.org/10.1016/0278-6915\(86\)90099-2](https://doi.org/10.1016/0278-6915(86)90099-2)
18. Leighton J, Nassauer J, Tchao R. The chick embryo in toxicology: an alternative to the rabbit eye. *Food and Chemical Toxicology*. 1985 Fev; 23(2):293–8. [https://doi.org/10.1016/0278-6915\(85\)90031-6](https://doi.org/10.1016/0278-6915(85)90031-6)
19. Sebbag L, Park SA, Kass PH, Maggs DJ, Attar M, Murphy CJ. Assessment of tear film osmolarity using the TearLab™ osmometer in normal dogs and dogs with keratoconjunctivitis sicca. *Veterinary Ophthalmology*. 2016 Oct 20;20(4):357–64. <https://doi.org/10.1111/vop.12436>
20. Petersen-Jones SM, Crispin SM, British. BSAVA manual of small animal ophthalmology. 2ª ed. Gloucester: British Small Animal Veterinary Association; 2002.
21. Cushnie TPT, Lamb AJ. Antimicrobial activity of flavonoids. *International Journal of Antimicrobial Agents*. 2005 Nov;26(5):343–56. <https://doi.org/10.1016/j.ijantimicag.2005.09.002>
22. Paula-Ju W de, Rocha FH, Donatti L, Fadel-Picheth CMT, Weffort-Santos AM. Leishmanicidal, antibacterial, and antioxidant activities of *Caryocar brasiliense* Cambess leaves hydroethanolic extract. *Revista Brasileira de Farmacognosia*. 2006 Dec;16:625–30. <https://doi.org/10.1590/S0102-695X2006000500007>
23. Simões CMO. Farmacognosia : da planta ao medicamento. Florianópolis: Editora Da Ufsc ; Porto Alegre Editora Da Ufrgs; 1999.
24. Damico FM, Gasparin F, Ioshimoto GL, Igami TZ, Cunha JR. ADS, Fialho SL, et al. Intravitreal injection of polysorbate 80: a functional and morphological study. *Revista do Colégio Brasileiro de Cirurgiões*. 2017 Dec;44 (6):603–11. <https://doi.org/10.1590/0100-69912017006010>

25. Montanez Mercado EC, Sam Zavala SY, Solis Cespedes PA, Ramirez Julca M. Use of the flowers of *Cantua buxifolia* Juss in the preparation of eye drops for eye irritation. *Universidad Ciencia y Tecnología*. 2022 Jun 30; 26(114):203–13. <https://doi.org/10.47460/uct.v26i114.605>.
26. Perches CS, Brandão CVS, Ranzani JJT, Pellizon CH, Donatti C, Fonzar JF, et al. Uso do colírio de *Citrus lemon* em úlceras de córnea induzidas em coelhos. *Arquivo Brasileiro de Medicina Veterinária e Zootecnia*. 2012 Oct; 64(5):1161–8. <https://doi.org/10.1590/S0102-09352012000500012>.
27. Dias FGG, Jorge AT, de Freitas Pereira L, Furtado RA, Ambrósio SR, Bastos JK, et al. Use of *Copaifera multijuga* for acute corneal repair after chemical injury: A clinical, histopathological and toxicogenetic study. *Biomedicine & Pharmacotherapy*. 2017 Dec;96:1193–8. <https://doi.org/10.1016/j.biopha.2017.11.099>
28. Curto EM, Labelle A, Chandler HL. *Aloe vera*: an in vitro study of effects on corneal wound closure and collagenase activity. *Veterinary Ophthalmology*. 2014 Mar 25;17(6):403–10. <https://doi.org/10.1111/vop.12163>.
29. Lisbão CBS, Corrêa MA, Ortiz JPD, Martins BC, Laus JL. Effects of the *Ottonia martiana* Miq. (Piperaceae) extract on dog's ocular surface. *Arquivo Brasileiro de Medicina Veterinária e Zootecnia*. 2012 Jun; 64(3):577–84. <https://doi.org/10.1590/S0102-0935201200030>.
30. Portier CJ, Hoel DG. Optimal design of the chronic animal bioassay. *Journal of Toxicology and Environmental Health*. 1983 Jul 1; 12(1):1–19. <https://doi.org/10.1080/15287398309530403>
31. Ritz, C, Baty, F, Streibig, JC., & Gerhard, D. Dose-response analysis using R. *PLoS One*, 10(12), e0146021. 2015. <https://doi.org/10.1371/journal.pone.0146021>
32. Seber, G. A. F., & Lee, A. J. *Linear Regression Analysis* (2nd ed.). Wiley. 2012. DOI: <https://doi.org/10.1002/9780471722199>