






# Surgical Correction of Metatarsal Angular Deviation in a Thoroughbred Filly Using Wedge Metatarsal Ostectomy: a case report

## Correção Cirúrgica de Desvio Angular Metatársico em uma Potra Puro-sangue Utilizando Ostectomia em Cunha: um relato de caso

José Ademar Villanova Junior<sup>1</sup> , Mônica Maciel<sup>1\*</sup> , Pedro Augusto Lara<sup>1</sup> , Luane Camargo Zeni<sup>1</sup> , Carlos Eduardo Camargo<sup>1</sup> , Luiz Guilherme Achcar Capriglione<sup>1</sup> , Pedro Vicente Michelotto Junior<sup>1</sup> 

<sup>1</sup>Pontifícia Universidade Católica do Paraná (PUCPR), Curitiba, Paraná, Brazil

\*Corresponding author: [monica.mm.maciel@gmail.com](mailto:monica.mm.maciel@gmail.com)

### Abstract

This study describes a corrective procedure for a metatarsal angular malformation using wedge ostectomy in a 41-day-old Thoroughbred filly. A 41.6° angular malformation of the metatarsus was corrected with wedge ostectomy of the left hindlimb in association with a type II external fixator and methyl methacrylate resin. The animal was subjected to the surgical procedure under general anesthesia. The filly was placed in dorsal recumbency with the left hind limb free for manipulation. A bone saw was used for the wedge ostectomy, while the bars for external fixation were placed using a drill. A Kirschner pin and acrylic resin were then applied. Radiographic images obtained immediately after surgery confirmed a total malformation reduction of 32.6 (from 41.6° to 9°). With medication and a Robert Jones bandage, intensive postoperative care was instituted to ensure that the animal adapted properly to the linear external fixator without overloading the pins and connection bars. No postoperative complications were observed. On the day after surgery, the filly was standing and walking with no signs of pain. After 180 days, total osseous calcification was achieved, and the implants were removed during the second surgery. The filly demonstrated adequate locomotion, performed all the movements, and ran without any difficulty in the paddock. The remaining discrete angular deviations were partially corrected using hoof trimming.

**Keywords:** Equine; foal; third metatarsus; angular limb deformity; ostectomy.

### Resumo

O objetivo desse estudo é descrever o procedimento de correção da malformação de desvio angular metatársico, utilizando ostectomia em cunha, em uma potra puro-sangue de 41 dias de idade. Uma malformação metatársica angular de 41,6° foi corrigida com a técnica de ostectomia em cunha, em associação com fixador externo tipo II e resina de metilmetacrilato, no membro pélvico esquerdo. O animal foi submetido à cirurgia sob protocolo de anestesia geral. A potra foi posicionada em decúbito dorsal, com o membro pélvico esquerdo livre para manipulação. Para a realização da ostectomia em cunha, foi utilizada uma serra óssea. Para a instalação das barras do fixador externo, uma furadeira foi utilizada e, para fixá-los, pinos de Kirschner e resina acrílica foram aplicados. Logo após a cirurgia, imagens radiográficas foram obtidas para confirmar a redução total de 32,6° (de 41,6° para 9°) de angulação. Para garantir que o animal se adaptasse ao fixador externo linear e não sobrecarregasse os pinos e barras, foram instituídos cuidados pós-operatórios intensos, com medicações e bandagem de Robert Jones. Não houve complicações no pós-operatório. No dia seguinte à cirurgia, a potra estava em pé, caminhando e sem sinais de dor. Após 180 dias, alcançou total calcificação óssea e os implantes puderam ser removidos em um segundo tempo cirúrgico. A potra demonstrou locomoção adequada, realizando todos os movimentos normais e pôde correr pelo pasto sem dificuldades. Um discreto desvio angular remanescente foi parcialmente corrigido por casqueamento.

**Key words:** Equino; potro; terceiro metatarso; deformidade angular do membro; ostectomia.

## 1. Introduction

Congenital angular deformities of the diaphysis of the third metatarsus are rare in foals. The deviation is primarily located in the middle to proximal regions of the bone, with the etiology remaining uncertain<sup>(1,2)</sup>. Previous studies have suggested that abnormal fetal positioning

and vascular anomalies related to nutritional foramina may contribute to inadequate bone development<sup>(3,4)</sup>. The diagnosis of this condition is primarily based on clinical examination; however, radiographic evaluation is considered the gold standard for definitive diagnosis, as it allows for the assessment of the degree of angulation and involvement of the proximal and distal joints<sup>(2,5)</sup>.

Received: January 27, 2023. Accepted: April 12, 2023. Published: May 22, 2023.



This is an Open Access article distributed under the terms of the Creative Commons Attribution License, which permits unrestricted use, distribution, and reproduction in any medium, provided the original work is properly cited.

<https://revistas.ufg.br/vet/index>

The purpose of this study was to report the use of wedge ostectomy as a surgical option for the correction of a congenital large angular deviation of the third metatarsus in a Thoroughbred filly, with the aim of preserving the animal's high genetic value. The results of the surgical intervention and postoperative complications are discussed below.

## 2. Case report

### 2.1 History, clinical examination, and diagnosis

A Thoroughbred filly was found to have a significant congenital angular deformity in the third metatarsal of the left pelvic limb at birth (Figure 1A). No other skeletal abnormalities were noted, and the foal was reported to be adequately nursing and displayed normal behavior. However, the filly presented with lameness on weight-bearing. Radiographic examination was performed on the first day of life to evaluate the extent of deformity. Images of the affected (Figures 1B and 1C) and contralateral limbs were obtained. Biochemical tests, including complete blood count and serum alanine aminotransferase (ALT), alkaline phosphatase (AL), albumin, urea, and creatinine levels, were performed the following week, and the results were within normal limits.

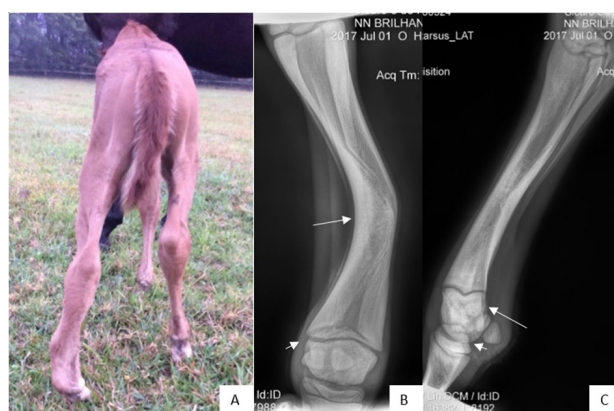At 20 days of age, the filly was separated from the dam and transferred to an institutional large animal facility for further management. On physical examination, the filly was found to be normohydrated without any changes in physiological parameters. The fillies were fed a diet composed of bovine milk diluted with glucose and water administered every 12 h, commercial foal feed containing 25% crude protein offered every 8 h, and mineral salt and Tifton hay offered ad libitum owing to early weaning.

Owing to the progressive worsening of the angular deformity, with a deviation of  $41.6^\circ$  and a corresponding increase in lameness, surgical intervention was deemed necessary. Wedge ostectomy was performed to realign the metacarpal bone of the third metatarsus. A video of the examination performed at 20 days of age is shown in supplementary material.

### 2.2 Anesthetic and surgical procedure

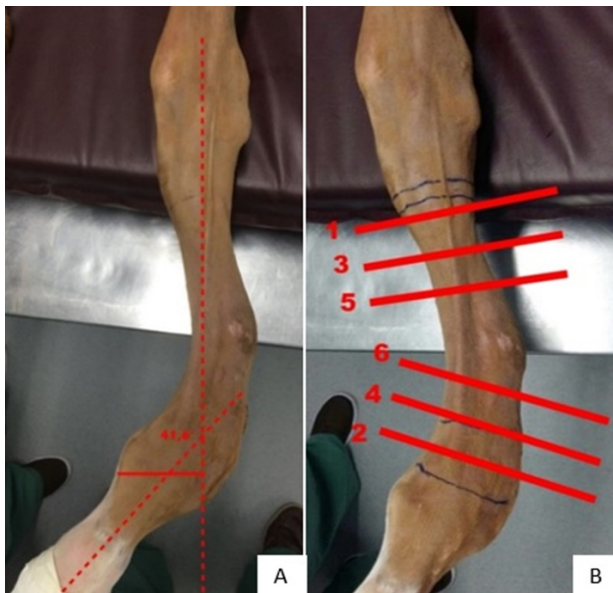Prior to the procedure, the animal were placed on a four-hour food and water fast. Premedication was administered via intravenous (IV) injection, consisting of midazolam at a dosage of 0.2 mg/kg in conjunction with methadone at a dosage of 0.1 mg/kg. Aseptic venous catheterization of the right and left external jugular veins was then performed for the administration of lactate ringer (10 mL/kg/h) and additional medications. Subsequently, spinal anesthesia was administered in the

lumbosacral space, utilizing a combination of morphine (10 mg/mL) at a dosage of 0.1 mg/kg and ropivacaine (5 mg/mL) at a dosage of 0.05 mL/kg, in accordance with the technique described by Carpenter and Byron (2015)<sup>(4)</sup>. Anesthetic induction was achieved using IV ketamine at a dosage of 2.2 mg/kg administered intravenously in combination with midazolam (IV 0.1 mg/kg, with maintenance achieved by IV propofol at a rate of 0.1-0.6 mg/kg/min as needed. Intubation was performed using a 14-mm endotracheal tube, with the animal connected to a circular semi-closed respiratory system utilizing 100% oxygen at a flow rate of 5-6 L/min during spontaneous breathing.



**Figure 1.** One-day-old Thoroughbred filly (A), demonstrating significant varus deformity in the left third metatarsal bone. Dorsa-plantar (B) and latero-medial (C) radiographic images of the third left metatarsal bone. In (B), varus angular deformity of the third metatarsal and poor congruence of the metatarsal-phalangeal joint (shorter arrow) are present. Additionally, there is noticeable thickening of the cortical layer of the concave surface (arrow). In (C), abnormal bone alignment (arrow) and poor congruence of the metatarsal-phalangeal joint (shorter arrow) can be seen.

A maximal type II external fixator model, consisting of the passage of transosseous pins on both the lateral and medial sides of the bone, was used. Each transosseous pin represents 20% of the thickness of the transfixated bone region. The pin tips were interconnected by two connecting rods, one on each side<sup>(5; 6)</sup>. For pin placement during the wedge ostectomy procedure, a skin incision was made laterally to the third metatarsal, with the pins placed without reaching the growth lines and in the following sequence: pin 1, parallel to the proximal articular surface; pin 2, parallel to the distal articular surface; pin 3, parallel to pin 1; pin 4, parallel to pin 2; pin 5, parallel to pin 3; and pin 6, parallel to pin 4 (Figure 2B). The distance between the parallel pins was measured to ensure that the intervals were the same on the medial and lateral sides<sup>(6; 7)</sup>.

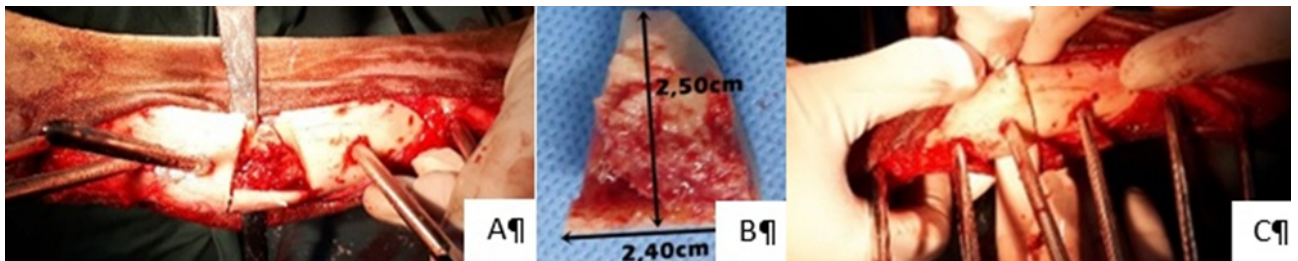


**Figure 2.** (A) Preoperative assessment of the angulation of the distal pelvic member of the 41-day-old Thoroughbred filly. There is an obvious deviation of  $41.6^\circ$ . (B) Blue lines, depicting the regions of the physical lines; numbered red lines correspond to the sequence of placement of transosseous pins.

The point of encounter between pins 5 and 6, proximal and distal to the curvature, respectively, determines the area of wedge ostectomy. Corticotomies

were then initiated, and the sagittal bone saw was cooled with 0.9% NaCl solution. The first corticotomy was performed parallel to pin 5 and reached only the first cortical region, whereas the second corticotomy was performed parallel to pin 6 and reached only the first cortical region. Partial-wedge ostectomy allowed visualization of the spinal canal and its respective vessels (Figure 3A), thereby avoiding significant hemorrhage. Further corticotomy was performed in the second cortex, parallel to pins 5 and 6. Each bone segment measured 2.4 x 2.5 cm in size (Figure 3B); in total, two bone segments of equal size and thickness were removed. Following bone excision (wedge ostectomy), the bone was realigned (Figure 3C), and the deviation decreased from  $41.6^\circ$  (Figure 2A) to  $9^\circ$  (Figure 4A).

The tips of the transosseous pins were interconnected using a methyl methacrylate base rod with an average final thickness of 4 cm. A Kirschner pin was placed within each connecting rod to increase stiffness and prevent bending. However, during the cutting of the excess of pin tips, resulted in misalignment of the ostectomy line. To rectify this, the methyl methacrylate base was opened to cut the connecting rod, radiographically resulting in the false appearance of a broken pin. The opened area was filled with methyl methacrylate again, without compromising the stability of the base rod. Radiographic evaluation confirmed the alignment of the epiphyses and diaphysis (Figure 4B).



**Figure 3.** (A) Operative image after removal of one of the cortices for visualization of the vessels of the medullary canal of the third metatarsal of the 41-day-old Thoroughbred filly. (B) Photographic image of the removed cortical layer (2.4 x 2.5 cm). (C) Bone realignment of corticotomy lines after wedge ostectomy.

### 2.3 Postoperative care

Dressing of the surgical site was performed with topical penicillin in the region of the transosseous pins; hydrophobic orthopedic cotton, crepe bandage, elastic bandage, plaster, and PVC (polyvinyl chloride biodegradable) plastic were used, and a Robert Jones bandage was applied<sup>(8)</sup>. Shortly after recovery from anesthesia, the animal was already supporting the operated limb, with no signs of discomfort. In the postoperative period, tramadol (intramuscular (IM) tramadol hydrochloride 2.5 mg/Kg every 12 hours during

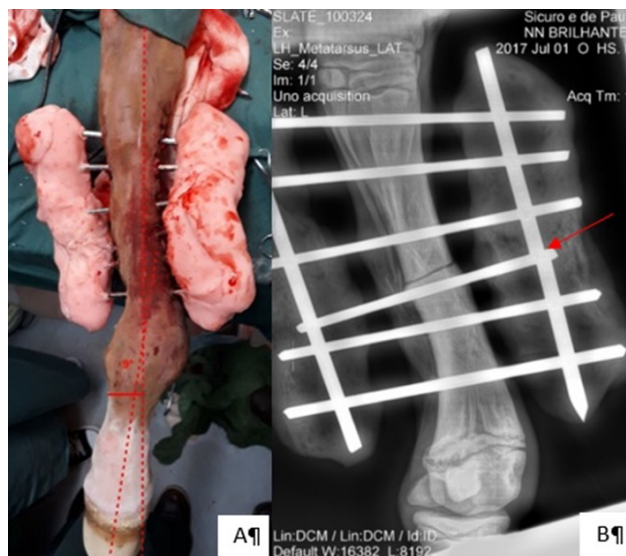
four days), meloxicam (meloxicam 0.6 mg/Kg/IM every 24 hours for seven days), dipyrrone (IM dipyrrone monohydrate 50 mg/animal every 12 hours for seven days), penicillin (IM penicillin 20.000 IU/Kg every 24 hours for five days) and gentamicin (IV gentamicin 6 mg/Kg every 24 hours for five days) were used, and ceftiofur (IM ceftiofur 2.2 mg/Kg) in a single dose was used intraoperatively<sup>(4)</sup>.

### 2.4 Follow-up

On the day after surgery, the foal was observed to be standing and displaying no signs of pain.



Throughout the postoperative period, the filly showed positive clinical evolution. The dressings were changed at intervals of 10 days.

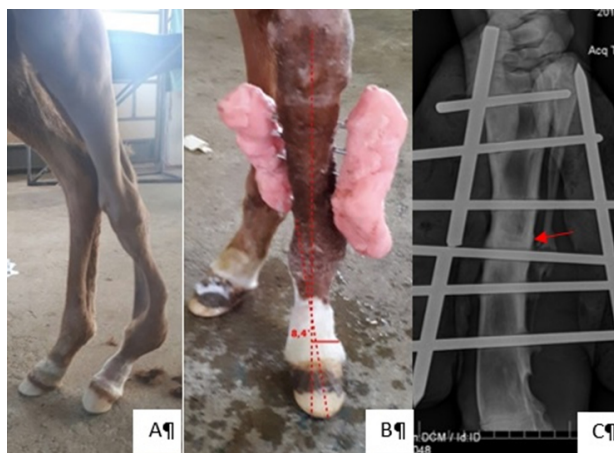


**Figure 4.** (A) Photographic image of the pelvic limb of the 41-day-old equine after wedge ostectomy of the third metatarsus and placement of external fixator. A 9° angle between the surfaces of the tarsometatarsal and metatarsophalangeal joints remained. (B) Radiographic image in dorsum-plantar incidence, shortly after the surgical procedure. Note the alignment of the epiphyses and the cutting region (arrow) of the pin that was placed inside the resin bar interconnecting the tips of the pins.

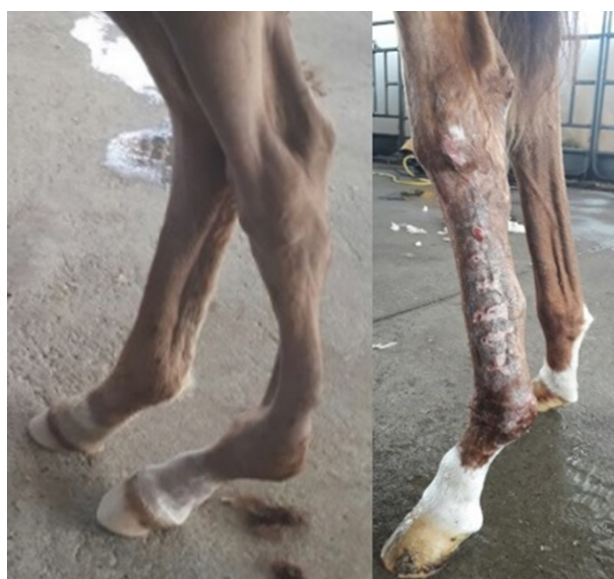The angular deviation of the limb was assessed prior to (Figure 5A) and immediately following the surgical procedure, resulting in a reduction of 32.6° (from 41.6° to 9°) by corrective hoof trimming on at 75 days postoperatively, achieving a final angular deviation of 8.4° (Figure 5B). Additional radiographic images were obtained at 21, 55, 120, and 180 postoperative days to monitor the surgical progress, revealing gradual formation of bone callus. There were no instances of bone lysis due to pin mobility, bone resorption, or osteomyelitis. Complete healing was observed after 180 days (Figure 5C) with no excessive bone callus formation.

Blood counts and preoperative biochemical tests were repeated on the same days as the radiographic examinations, with the results remaining within normal limits. During use of the external fixator, the animals were maintained with restrictions on space and activity. Following implant removal, the animal demonstrated increased activity and at no point did it cease to use its operated limb. The surgical intervention was successful, and after observing the patient for nine months, it can be concluded that the animal was able to perform normal activities, including walking, trotting, and running, despite a slight rotation of the metatarsophalangeal joint,

observed after the removal of the external fixator, performed 190 days after the surgical procedure (Figure 6B).



**Figure 5.** (A) Photograph of the pelvic limb of the Thoroughbred filly. A marked varus deviation due to the deformity of the third metatarsus is noted. (B) Photograph of the same limb after 75 days of wedge ostectomy, stabilization with the external fixator, and corrective casing. Note the 8.4° remaining angle between the surfaces of the tarsometatarsal and metatarsophalangeal joints. Thoracic-plantar radiographic image (C) of the third left metatarsal of the Thoroughbred filly, at 221 days of age and 180 days after wedge ostectomy and external fixator placement. Note the full bone healing (arrow) in the line where the bone excision had been performed.



**Figure 6.** (A) Photographic image of pelvic member of equine at 41 days of age. A marked varus deviation is noted due to the deformity of the third metatarsus. (B) Photographic image of the same member, at 10 days after removal of the external fixator.

### 3. Discussion

The case presented is a rare congenital disease in horses. Only a few similar studies have been found, and most publications are bibliographic reviews and retrospective studies on less invasive surgical procedures used to treat mild deformities <sup>(2, 9)</sup>.

The use of external fixation in foals is relatively uncommon because of the increased postoperative care requirements and potential for complications such as osteomyelitis, implant loosening, or breakage. Alternative correction methods, such as transfixing bridges made on the convex side of the shaft using screws and wires, a single transfixing screw, or bone plates and screws, are commonly utilized. It is important to note that the use of external fixation should be carefully considered, and the benefits outweigh the risks. The decision to use external fixation should be based on the features of each case and on the surgeon's experience and expertise. <sup>(2; 9; 10)</sup>. However, external fixation has also been used in equine species, including in older animals <sup>(5)</sup>. We believe that surgery at 41 days of life constitutes early intervention, avoiding further damage to the adjacent joints, mainly the fetlock, which has fast growth rates in the first months of life <sup>(2)</sup>. The precocity of the intervention also helped in the possibility of the other joints compensating for the smaller extension of a metatarsal, if compared to the contralateral limb, since the other joints of the operated limb can be closer to 180° <sup>(7, 6)</sup>. In addition, the use of an external fixator allowed accurate calculation of the osteotomy area, as the introduction of the transosseous pins was calculated and progressively applied.

To interconnect the transosseous pins, a Kirschner pin and a connecting rod with acrylic resin were used, which were functional and resistant throughout the postoperative period. A resin thickness of approximately 4 cm is equivalent to a patient's bone thickness. This relationship is similar to that used in dogs of large breeds, in which the resin thickness is 2 cm, which is equivalent to bone thickness <sup>(6)</sup>.

Misalignment of the bone was observed upon drying and hardening of the acrylic resin. However, the use of a Kirschner pin and acrylic resin for transosseous pin stabilization facilitated realignment of the transosseous pins. The Kirschner pin was cut, and the resin was serrated to achieve the desired realignment of the transosseous pins. Once realigned, a new layer of resin was applied to stabilize the connecting rod as previously described <sup>(7)</sup>. A sterile mold of the metatarsal deviation, determined using radiographs obtained during surgical planning, can be used to increase the precision of the osteotomy area. Although residual deviation may occur, primarily at the fetlock joint, it should not impede the proper use of the limb in adulthood.

Most cases of congenital limb deviation in foals

are due to ligament or muscle laxity. Important deviations are commonly related to premature birth, twin birth, placentitis, soft tissue trauma at birth, and flaccidity of the structures supporting the joints <sup>(13)</sup>. The orthopedic deformity involving only the left third metatarsal bone in this field was probably due to poor intrauterine position since there were no nutritional, metabolic, or endocrine changes.

A significant deviation was observed in this study, and the severity of the deformity was incompatible with life in adulthood. Substantial angulation of one joint restrains the adequate load distribution across the other joints of the limb. In the long term, there would be a poor distribution of weight in the other three limbs and improper angulations in all joints of the abaxial skeleton, even reaching the axial skeleton. The result of these poor angulations would be functional limb loss, lameness, chronic pain, and reluctance to engage in physical activity <sup>(2; 11; 12; 13)</sup>.

After surgery, adequate growth, no developmental disease, and good integumentation and bone healing were observed. Nonluxuriant bone callus formation, as observed in the present study, demonstrated full blockade of the five forces of rupture (tension, compression, flexion, and shear) acting around the area of osteotomy <sup>(6)</sup>. In addition, the absence of a history of similar family illnesses throughout the lineage should be noted. Signs compatible with syndromes that could be transmitted to offspring were not observed in the fillies. In addition, there was no history of similar family diseases throughout the lineage.

Osteoporosis was observed in the osteotomized region during the implant removal. This could have been avoided if the external fixator had been maintained for a shorter period, and a monthly radiographic follow-up could be suggested for better monitoring of the time of implant removal immediately after the formation of adequate bone callus. Multiple factors, including cost, were involved in the choice of the surgical technique in the present case. Ultimately, an efficient and low-cost technique is presented. Moreover, external fixation of the skeletal muscle results in complete weight-bearing of the limb during the postoperative period, as evidenced in the present case. This proved to be a major advantage of the technique, considering further risks such as hyperextension deformity of the contralateral limb <sup>(14)</sup>. Finally, the use of an external fixator in equine species is challenging, and we believe that an excellent result was obtained in the present case because the technique was used in a young, light, and active patient.

### 4. Conclusions

In conclusion, wedge osteotomy is an effective surgical option for correction of congenital angular

deviation of the third metatarsus in foals. The procedure resulted in significant improvement in the alignment of the affected limb and a marked reduction in lameness. Further studies are required to evaluate long-term outcomes and potential complications of this surgical technique.

#### Supplementary material

Video 1 - [Filly with 21 days.](#)

Video 2 - [Surgery recovery.](#)

Video 3 - [7 months after the surgery.](#)

Video 4 - [18 months after the surgery.](#)

#### Conflict of interest

All authors declare no conflict of interest.

#### Author contributions

*Conceptualization:* P. A. Lara. *Investigation:* J. A.V. Junior, M. Maciel and P. A. Lara. *Resources:* L. C. Zeni, C. E. Camargo and L. G. A. Capriglione. *Supervision:* P. V. M. Junior. *Writing (original draft):* J. A.V. Junior. *Writing (review & editing):* M. Maciel.

#### Acknowledgements

We thank Professor Enio Moura for the technical support in veterinary genetics.

#### References

- Bertone AL. (2011). Angular limb deformities associated with the diaphysis of the third metacarpal and metatarsal bones (Cannon bone). In: Baxter GM, ed. Adams & Stashak: Lameness in Horses. 6th ed. Hoboken, NJ: Wiley-Blackwell; 636-637.
- McCarrel TM. (2017). Angular limb deformities – Growth retardation. *Veterinary Clinics of North America: Equine Practice.* 33: 353-366. DOI: <https://dx.doi.org/10.1016/j.cveq.2017.03.006>
- O'Grady SE. (2017). Routine trimming and therapeutic farriery in foals. *Veterinary Clinics of North America: Equine Practice.* 33:267-288. DOI: <https://dx.doi.org/10.1016/j.cveq.2017.03.012>
- Carpenter RE, Byron CR. (2015). Equine Local Anesthetic and Analgesic Techniques. In: Grimm KA, Lamont LA, Tranquilli WJ, Greene SA, Robertson SA, eds. *Veterinary Anesthesia and Analgesia.* 5th ed. Hoboken, NJ: Willey-Blackwell; 904.
- Sullins KE, McIlwraith W. (1987). Evaluation of 2 types of external skeletal fixation for repair of experimental tibial fractures in foals. *Veterinary Surgery.* 16:255-264. DOI: <https://doi.org/10.1111/j.1532-950X.1987.tb00949.x>
- Johnson AL. (2015). Fundamentals of Orthopedic Surgery and Fracture Management. In: Fossum TW. *Small Animal Surgery,* 4th ed. Maryland, MO: Mosby; 1033-1105.
- Denny HR, Butterworth SJ. (2006). *Orthopedic surgery in dogs and cats.* 4th ed. São Paulo, SP: Roca; 396-427.
- Lutter JD, Cary JA, Stephens, RR, Potts, LB. (2015). Relative stiffness of 3 bandage/splint constructs for stabilization of equine midmetacarpal fractures. *Journal of Veterinary Emergency and Critical Care.* 25:379-387. DOI: <https://doi.org/10.1111/vec.12299>
- Witte S, Hunt R. (2009). A review of angular limb deformities. *Equine Veterinary Education.* 21:378-387. DOI: <https://doi.org/10.2746/095777309X440096>
- Getman LM. (2011). Surgical treatment of severe, complex limb deformities in horses. *Equine Veterinary Education.* 23:386-390. DOI: <https://doi.org/10.1111/j.2042-3292.2011.00242.x>
- Caron JP. (1988). Angular limb deformities in foals. *Equine Veterinary Journal.* 20:225-228. DOI: <http://doi.org/10.1111/j.2042-3306.1988.tb01508.x>
- Trumble TN. (2005). Orthopedic Disorders in Neonatal Foals. *Veterinary Clinics of North America: Equine Practice.* 21:357-385. DOI: <http://doi.org/10.1016/j.cveq.2005.04>.
- García-Lopez JM. (2017). Angular limb deformities: Growth Augmentation. *Veterinary Clinics of North America: Equine Practice.* 33:343-351. DOI: <http://doi.org/10.1016/j.cveq.2017.03.005>
- Aithal HP, Kinjavdekar P; Amapal, Pawde AM, Zama NMS, Dubey P, Kumar R, Tyagi SK, Madhe DN. (2019) Epoxy-Pin External Skeletal Fixation for Management of Open Bone Fractures in Calves and Foals: A Review of 32 Cases. *Veterinary and Comparative Orthopaedics and Traumatology.* 1:1-12. DOI: <http://doi.org/10.1055/s-0039-1678736>