









## The macroscopic and microscopic description of ruminal lesions in feedlot bovine

### *Descrição macroscópica e microscópica das lesões ruminais em bovinos confinados*

Paulo Roberto Lucas Viana<sup>1</sup> , Letícia Fleury Viana<sup>2</sup> , Gustavo Henrique Marques Araújo<sup>3</sup> , Isadora David Tavares de Moraes<sup>4</sup> , Paulo José Bastos Queiroz<sup>4</sup> , Didier Quevedo Cagnini<sup>3</sup> , Luiz Antônio Franco da Silva<sup>4</sup> , Rogério Elias Rabelo<sup>5\*</sup> 

<sup>1</sup>Agência Goiana de Defesa Agropecuária (Agrodefesa), Goiânia, Goiás, Brazil

<sup>2</sup>Instituto Federal Goiano (IF Goiano), Rio Verde, Goiás, Brazil

<sup>3</sup>Universidade Federal de Jataí (UFJ), Jataí, Goiás, Brazil

<sup>4</sup>Universidade Federal de Goiás (UFG), Goiânia, Goiás, Brazil

<sup>5</sup>Aprimory Vet, Jataí, Goiás, Brazil

\*Correspondent: [rabelovet@yahoo.com.br](mailto:rabelovet@yahoo.com.br)

#### Abstract

Administration of diets rich in highly fermentable carbohydrates and low fiber content can cause an imbalance between the microorganisms in the rumen with consequent ruminal acidosis. This problem can cause lesions in the rumen wall, often progressing to rumenitis. The purpose of the present was to characterize macroscopic and microscopic ruminal lesions observed in confined feedlot cattle with claw lesions or liver abscess. A total of 1060 bovines were evaluated via postmortem examination. Claw lesions were identified in 88, liver abscess in 10, and macroscopic rumen lesions in 230 bovines; furthermore, 178 rumens were characterized with hyperkeratosis, 41 with hyperemia, 9 with ulcer, and 2 with neoplasia. The 98 bovines with claw lesions and liver abscess were selected for histopathological examination. Of these, macroscopic lesions were noted in 23 and microscopic lesions in 23 animals. Of the 23 animals that presented macroscopic lesions, 10 showed the same changes observed under microscopy. Seven cases of hyperkeratosis were diagnosed in the macro and microscopic evaluation. Of the 5 cases of hyperemia verified on macroscopy, 2 cases were identified via microscopy, and 1 case of ulcer identified through macroscopy and microscopy. The microscopic evaluation of the rumens allowed the identification of lesions in animals with claw lesions that did not present macroscopic rumen alterations.

**Keywords:** cattle; fridge; histopathology; rumen; rumenitis.

#### Resumo

O uso de dietas ricas em carboidratos altamente fermentáveis e com baixos teores de fibras pode ocasionar desequilíbrio entre os microrganismos do rúmen com consequente acidose ruminal. Esse problema pode resultar em lesões na parede do rúmen, evoluindo com frequência para formação de ruminite. O presente estudo objetivou caracterizar lesões ruminais macroscópicas e microscópicas, observadas em bovinos confinados que apresentavam lesões podais ou abscesso hepático. Avaliou-se 1060 bovinos pelo exame *post mortem*. Foram encontradas lesões podais em 88 animais, abscesso hepático em 10 e lesões ruminais macroscópicas em 230 bovinos, sendo caracterizado 178 rumens com hiperqueratose, 41 com hiperemia, 9 com úlcera e 2 com neoplasia. Os 98 bovinos com lesões podais e abscesso hepático foram selecionados para realização de exame histopatológico. Desses, foram encontradas lesões macroscópicas em 23 e, microscópicas, em 23 animais. Dos 23 animais que apresentaram lesões macroscópicas, 10 tiveram as mesmas alterações verificadas na microscopia. Foram diagnosticados 7 casos de hiperqueratose na avaliação macro e microscópica. Dos 5 casos de hiperemia verificados na macroscopia, 2 casos foram identificados na microscopia e um caso de úlcera identificado na macroscopia também foi identificado na microscopia. A avaliação microscópica dos rumens permitiu identificar lesões em animais com lesões podais que não apresentam alterações macroscópicas ruminais.

**Palavras-chave:** bovinos; frigorífico; histopatologia; rúmen; ruminite.

Received: June 13, 2022. Accepted: September 19, 2022. Published: October 7, 2022.



## Introduction

The search for increased productivity and quality and reduction of production costs is a necessity in the different systems of cattle breeding. In this scenario, genetics, health, reproduction, and nutrition, guided by biotechnologies, are included. Technological development and improvement, the use of diets rich in highly fermentable carbohydrates and low fiber contents have become indispensable for the improvement of animal nutrition in several cattle breeding systems. However, the unbalanced use of concentrated feed and feed management errors increase the risk of metabolic disorders, which can result in damage to the bovine health. This may consequently decrease the zootechnical performance<sup>1,2</sup>. Notably, ruminal acidosis stands out among the main metabolic disorders identified in intensive cattle breeding<sup>1</sup>.

Rumen acidosis is a digestive disease that occurs in non-adapted ruminants when they ingest large amounts of soluble carbohydrates or have sudden changes in their diet, causing an imbalance between the production of volatile fatty acids (VFAs) and their removal by the ruminal epithelium<sup>1</sup>. The reduction in intraruminal pH affects the balance between ruminal microorganisms with the involvement of Gram positive bacteria, such as *Streptococcus bovis* and *Lactobacillus spp.*, reducing the number of cellulolytic bacteria to the detriment of aminolytic bacteria<sup>2-5</sup>. Ruminal acidosis can be acute or subacute. Acute ruminal acidosis is characterized by the sudden decrease in rumen pH, being of multifactorial origin. However, the subacute ruminal acidosis is mild, and may be continuous or intermittent, resulting in less immediate risk to animals<sup>6</sup>.

Therefore, acidosis can lead to secondary alterations in the bovine rumen wall, such as rumenitis. In addition, the issues related to this organ may be highlighted by an inspection service, which will lead to financial losses in cases when abscesses are detected. In addition, bacterial colonization in wounds exacerbates symptoms of rumenitis, and these microorganisms may enter the liver via portal circulation, which can result in additional damage caused by the formation of liver abscesses that would lead to organ condemnation<sup>3,7,8</sup>. Despite being a disease of multifactorial and controversial etiology, acute or subacute acidosis is characterized as the main etiopathological factors associated with laminitis and its sequelae in the herd<sup>9</sup>.

Although the diagnosis of acute ruminal acidosis is clinically simple, the same is not true in cases of subacute acidosis, which are apparently more harmful to the health of the animals<sup>1,10</sup>. The diagnostic conclusion is typically established during the slaughter of the animals. This is attributable to the fact that the pertinent problem is neglected by nutritionists and cattle breeders during the finishing phase. Therefore, *postmortem* macroscopic

analysis in beef and dairy cattle performed in a slaughterhouse provides a series of findings indicative of past acidosis. In this context, rumenitis is the most described lesion, characterized by the presence of hyperemic, hemorrhagic, or ulcerated mucosa as a result of low ruminal pH in the ventral sac rumen<sup>2,6,11,12</sup>. Improving the identification of discrete ruminal lesions of acidotic origin may be possible using histopathology as a complementary assessment technique, which can be valuable in understanding the real prevalence of subacute rumenitis. This may subsequently help breeders and nutritionists to modulate dietary balance in stages of breeding.

The purpose of the present study was to describe, through macroscopic and microscopic examinations, ruminal lesions observed in Nellore cattle with a positive diagnosis for claw lesions and or liver abscess, managed on pasture during breeding and raising in a confinement system during finishing phase. Another aim was to compare the ability to identify discrete macroscopic lesions using histopathological evaluation as the gold standard.

## Material and methods

A total of 1060 male Nellore cattle, aged between 20 and 30 months, managed on pasture during breeding and raising and in a confinement system during finishing phase were evaluated. The macroscopic evaluations and the collection of samples for microscopic analysis were performed in a beef slaughterhouse under the Federal Inspection Service (FIS), located in the municipality of Jataí, Goiás from July to December 2016. The ethical precepts in animal experimentation were obeyed, being approved by the ethics committee in the use of animals of the Federal University of Goiás, under protocol number 071/15. The choice of the meat refrigerator company was based on the availability of the establishment's owners to authorize the research. The evaluation was based on the slaughterhouse data, with a greater number of confined animals slaughtered. Therefore, using bovines of the same sex, coming from a single production system, and at the same time of year may be possible.

During the finishing phase, all evaluated cattle were kept in a confinement system for an average period of 70 days, after the adaptation period of 21 days with a diet containing the same ingredients; however, in different proportions. Slaughter monitoring was divided into five stages, the *antemortem* examination followed by *postmortem* examination of the claw in "line A" and *postmortem* examination of the liver in "line E," according to the inspection methodology recommended by MAPA (Ministry of Agriculture, Livestock and Supply)<sup>13</sup>. Subsequently, in the tripe room (first phase), two activities were carried out, the macroscopic

evaluation of the rumen of a total of 1060 animals and the collection of material for histopathological evaluation.

Before slaughter, a general evaluation of the animals in the pens at the slaughterhouse was performed. Anamnesis data were collected from the Animal Transit Guide (ATG). Macroscopically, the four distal extremities of the locomotor limbs, liver, pre-stomachs, and abomasum were evaluated, with the findings related to the corresponding carcass<sup>13</sup>. In all cases in which the animals had claw or liver lesions, samples from the rumen were collected to try to connect whether or not they were related to macro or microscopic lesions. The limbs were evaluated in the presence of claw lesions, as described in the literature<sup>29,30</sup>. In the liver, only the abscess lesions were included.

Digestive anatomical structures, including the reticulum, rumen, omasum, and abomasum, were identified with a specific pen in the serosa of the organ immediately after reaching the inspection tables. The markings correlated the viscera with the corresponding carcass; the organs were then diverted by a stainless steel structure from the slaughter room to the tripe room (first phase). After arriving at the tripe room, the organs were organized in numerical sequence to perform the routine emptying, hanging, and cleaning procedures. The rumen mucosa was then evaluated macroscopically and classified as follows: (1) **without lesion**: the coloration, appearance, and papillae of the rumen showed the absence of macroscopic lesions; (2) **hyperemia**: the rumen showed reddened areas; (3) **ulcer**: the rumen showed evident macroscopic ulcers; (4) **hyperkeratosis**: palpation, thicker areas of the epithelium, with the presence of firm and not very flexible papillae were observed; (5) **neoplasms**: papillomas, squamous cell carcinoma, or lymphomas were present; and (6) **abscesses**: the rumen showed abscesses. When the rumen presented any alteration that did not fit any of the established classifications, it was classified as (7) **undefined lesion**.

Owing to financial limitations, samples for histological evaluation were collected only from bovines that presented claw lesion and/or liver abscess, regardless of whether or not they presented macroscopic lesions in the rumen. In cases considered macroscopically “without lesion,” collection was performed in the ventral sac of the rumen, considering the commercial preservation of the viscera. In the presence of a lesion, an attempt was made to collect the fragment in the transition region of the lesion. All samples were immediately stored in 10% buffered formalin solution. After fixation, the fragments were dehydrated in ascending solutions of alcohol, deparaffinized in xylene, and embedded in liquid paraffin in order to make the histological blocks. The fragments were cleaved at 5  $\mu$ M in a rotating microtome, and the tissues were arranged on histological slides,

deparaffinized, hydrated, and stained with Hematoxylin and Eosin<sup>14</sup>.

Through microscopic evaluation, the ruminal lesions were classified as follows: (1) **absence** of lesion; (2) **mild acute rumenitis**, in the presence of mild to moderate congestion and mild inflammatory infiltrate; (3) **moderate acute rumenitis**, when moderate congestion and moderate inflammatory infiltrate and/or microabscesses are present; (4) **severe acute rumenitis**, when there was moderate to severe congestion, marked presence of inflammatory cells and/or microabscesses; (5) **chronic rumenitis**, when mononuclear, granulomatous, or pyogranulomatous infiltrate is present, with or without fibroblast proliferation, neovascularization and epithelial hyperplasia and (6) **scar or ulcer in healing**, when there is a discrete inflammatory infiltrate, at most moderate, with an evident proliferation of dense connective tissue and signs of re-epithelialization at the edges of the ulcer.

The results of macro and microscopic evaluations were submitted to descriptive statistics<sup>15</sup>. Microscopic evaluation was considered the gold standard for evaluating the sensitivity and specificity of macroscopic diagnosis.


## Results and discussion

Of the total of 1060 cattle that had the rumen evaluated macroscopically, lesions were observed in 230 (21.7%) animals, whereas 830 (78.3%) had no lesions (Table 1). Among the lesions, hyperkeratosis, hyperemia, ulcers, and neoplasms were identified (Figure 1).

**Table 1.** Macroscopic evaluation of the rumen and classification according to the degree of lesion diagnosed in the *postmortem* examination of bovines aged between 20 and 30 months, Nellore breed and managed in the finishing phase in a confinement system, slaughtered in 2016, in a slaughterhouse of Goiás state

Classification	Occurrence	Percentage (%)
Rumen without lesion	830	78.3
Hyperemic rumen	41	3.9
Ulcerated rumen	9	0.9
Rumen with hyperkeratosis	178	16.8
Rumen with neoplasms	2	0.2
Rumen with abscesses	0	0.0
<b>TOTAL</b>	<b>1060</b>	<b>100</b>





**Figure 1.** Macroscopic evaluation of bovine rumen and classification according to the degree of lesion diagnosed in the *postmortem* examination. A) rumen without lesion. B) hyperemic rumen. C) ulcerated rumen. D) rumen with hyperkeratosis.

In the inspection of the hooves, 88 animals with claw lesions were found, of which, 24 with interdigital dermatitis, 22 bovines with septic pododermatitis, 22 bovines with horn erosion. In addition, 16 cases of sole ulcer, 2 cases of nail fissure, 1 case of digital dermatitis, and 1 case of interdigital phlegmon. In the liver analyses, 10 cases of liver abscesses were diagnosed, not being correlated with claw lesions.

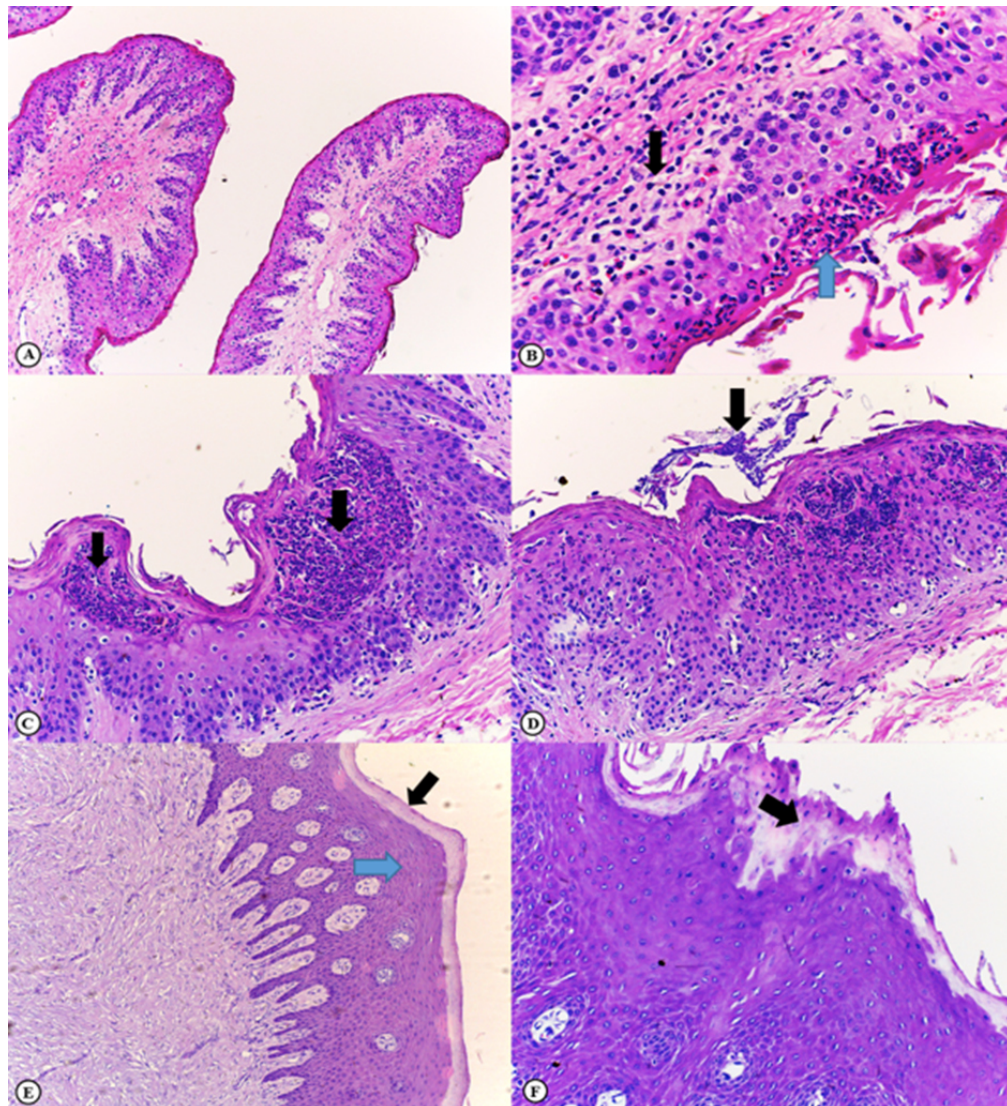
Among the 98 cases of animals with claw changes and/or liver abscesses, macroscopic lesions were identified in 23 (23.5%) and microscopic lesions in 23 (23.5%) animals (Table 2). Mild acute rumenitis (Figure 2) was the predominant change, followed by moderate and chronic acute rumenitis, with two cases each. There was only one case of lesion in the healing process (Figure 2). In addition, two cases of ruminal papillomatosis were identified.

**Table 2.** Macroscopic and microscopic evaluation of the rumen of cattle and classification according to the degree of lesion of 98 cattle with a positive diagnosis for claw lesions and liver abscess, aged between 20 and 30 months, Nelore breed and managed in the finishing phase in a confinement system, slaughtered in 2016, in a slaughterhouse in the state of Goiás

Evaluation	Description	Occurrence	Percentage (%)
Macroscopic*	Rumen without lesion	75	76.5
	hyperemic rumen	5	5.1
	Ulcerated rumen	1	1.0
	Rumen with hyperkeratosis	17	17.4
	Rumen with neoplasms	0	0.0
Microscopic**	Rumen with abscess	0	0.0
	Absence of lesion	75	76.5
	Mild acute rumenitis	16	16.3
	Moderate acute rumenitis	2	2.0
	Severe acute rumenitis	0	0.0
	Chronic rumenitis	2	2.0
	Healing scar or ulcer	1	1.0
	Papilloma	2	2.0

\*Assessment by *postmortem* examination

\*\*Evaluation by histopathology



**Figure 2.** Microscopic evaluation of the rumen of cattle and classification according to the degree of lesion diagnosed on histological slides of bovine with a positive diagnosis for claw lesions and liver abscess. **A) Normal rumen:** Normal ruminal papillae (100x, HE). **B) Mild acute rumenitis:** Note the focal, discrete presence of neutrophils in the superficial layer of the epithelium (blue arrow) and discrete mixed inflammatory infiltrate in the lamina propria (black arrow) (200x, HE). **C) Moderate acute rumenitis:** Multifocal, moderate, intraepithelial neutrophilic inflammatory infiltrate (black arrows) and mild parakeratotic hyperkeratosis (200x, HE). **D) Moderate acute rumenitis:** In addition to alterations described in C, note the presence of finely granular basophilic structures compatible with bacterial colonies above the keratinized layer (black arrow) (200x, HE). **E) Scar or ulcer in healing:** Re-epithelialized rumen. A layer of dense connective tissue in the submucosa, hyperplasia of the rumen epithelium (blue arrow) with papilla formation, and parakeratotic hyperkeratosis (black arrow) (40x, HE) are observed. **F) Scar or ulcer in healing:** Detail of hyperplastic epithelial layer and parakeratotic hyperkeratosis (black arrow) (400x, HE).

Of the 23 animals that presented macroscopic lesions, a correlation with microscopic lesions was identified in 10 cases (Table 3), i.e., 7 cases of hyperkeratosis, 2 cases of hyperemia, and 1 case of ulceration. The correlation found between microscopic and macroscopic diagnosis was 41.2% for cases of hyperkeratosis (7/17), 40% for cases of hyperemia (2/5), and 100% for only one case of ulceration (1/1). Two cases

of ruminal papillomatosis diagnosed on microscopy were not verified in the macroscopic evaluation. Probably the occurrence of an expressive amount of ruminants with the presence of hyperemia and hyperkeratosis indicates that, despite representing discreet alterations and without clinical repercussion, a representative part of the animals faced some level of aggression. These lesions could be explained, in part, by the change in the pasture diet for



confinement and exposure of these animals to the consumption of large amounts of concentrate, which can contribute to the occurrence of an imbalance between the production and removal of VFAs in the rumen, predisposing to ruminal acidosis<sup>16</sup>. Ruminal mucosa hyperemia and hyperkeratosis are adaptive responses that seek to protect the organ in early cases of low-intensity aggression, especially due to hyperkeratinization of the epithelium<sup>17-19</sup>.

Still considering the macroscopic findings evidenced in the rumen, the verified cases of ulcerated rumens could be attributable to some animals that had already arrived at the confinement with ruminal lesions in early stages and that were aggravated with the new diet or even due to the individual susceptibility of some animals. Although bovine gastrointestinal tract neoplasms are rare and more frequent in animals of advanced age<sup>20,21</sup>, the two cases diagnosed in this study were of papillomatosis. In addition to being an infectious disease caused by a virus, papillomatosis has a relatively higher frequency of occurrence in animals aged <3 years<sup>22</sup>.

The absence of ruminal abscesses and the several cases of cattle that did not present ruminal lesions in the macroscopic evaluation, in theory, can be justified by the fact that the animals were submitted to an adaptation diet before entering the feedlot<sup>18,23</sup>. Therefore, they were probably exposed to ruminal acidosis for a short time. Thus, the time of exposure to diets with the potential for ruminal acidosis to develop visible and diversified lesions may have been insufficient.

Using the classification of the macroscopic findings of the rumen proposed in this study, it was possible to identify the main ruminal lesions described in cattle with ruminal acidosis at different levels. A more segmented characterization of the macroscopic lesions made it possible to carry out a microscopic evaluation to analyze the stage of evolution of these lesions, representing an advance in this modality of study of ruminal lesions. Comparing the categorization used here with the stratification used by Rezac et al.<sup>24</sup>, it was more detailed and more elucidative, considering that the authors classified ruminal lesions using only three scores, normal, mild, and severe lesions. The classification proposed by Smith<sup>25</sup> into type I or “adherent flaps,” type II or “erosive rumenitis,” type III or “pseudomembranous rumenitis,” type IV or “ulcerative rumenitis,” type V or “scar retraction” and type VI or “adhered villi,” despite being more segmented, it was more complex to be used in experiments that require many animals analyses. Therefore, although the classification adopted here is more simplified, it allows the stratification of lesions in various stages of evolution, in addition to creating other scores such as hyperemia, neoplasms, and abscesses in the rumen. The macroscopic and microscopic results of the animals showed agreement in 43.5% of the cases, and

in 82.6% of the cases, the evaluation of healthy rumen was consistent with the microscopic result (Table 3).

**Table 3.** Contingency table for macroscopic evaluation of ruminal lesions considering microscopic diagnosis as the gold standard

Macroscopic evaluation	Lesion	No lesion	Sum
Lesion	10	13	23
No lesion	13	62	75
Total	23	75	
Sensitivity	43.5%		
False positives	56.5%		
Specificity	82.6%		
False negatives	17.4%		

In addition, 8 of the 10 animals (80%) that had liver abscesses did not present macroscopic ruminal lesions, while 90% (9/10) of these animals had microscopic ruminal lesions. No animal had claw lesions and concomitant liver abscesses.

Arguing about the microscopic evaluation of the rumen, which identified cases of mild acute rumenitis as the most frequent alteration in the present study, it can be suggested that, in the animals evaluated, the lesions were still in the initial stages of rumenitis, corroborating the macroscopic findings. These findings indicate that, possibly, the confinement diet used in the finishing phase of the animals did not result in acute acidosis enough to trigger significant lesions in the rumen wall, as described in several scientific studies<sup>19,26,27</sup>. It should be noted that the animals evaluated came from a producer that has been working with confinement systems for several years. Thus, management-related factors such as the animals' adaptation to changing diets, adequate nutritional balance, and a standardized feeding routine, including feeding several times a day, possibly resulted in the adaptation of the ruminal microbiota<sup>28</sup>, minimizing the effects of acidosis.

The microscopic evaluation showed a greater ability to identify initial lesions than the macroscopic evaluation, a fact demonstrated by the difference in the identification of ruminal lesions in cases of animals that had liver abscesses, where microscopy revealed 82.6% of ruminal lesions and, in the macroscopy, only 20% had ruminal lesions identified. This difference may indicate the greater sensitivity of microscopy to identify less pronounced lesions or be due to the fact that the initial macroscopic lesions of rumenitis have resolved or are in the resolution stage since pathophysiologically they precede the appearance of liver lesions.

Rumenitis, liver abscesses, and claw lesions, especially laminitis, are indicated as indicators of lesions secondary to ruminal acidosis<sup>3,8,9</sup>. Animals that are intensively managed and that receive diets rich in rapidly fermentable carbohydrates, such as confined cattle, dairy, and elite cattle, are likely to have a higher occurrence of ruminal lesions and, consequently, of liver abscesses and claw lesions. Therefore, the next step would be to evaluate the rumens of confined animals that do not present claw lesions or liver abscesses to compare the macro and microscopic findings in order to broaden the discussion with the results obtained by the present study.

## Conclusion

Macroscopic evaluation of Nellore cattle rumens with a positive diagnosis for claw lesions or liver abscess allowed to identify ruminal lesions in beef cattle, managed on pasture during breeding and raising in a confinement system during the finishing phase. The microscopic evaluation made it possible to detect ruminal lesions that went unnoticed by the macroscopic evaluation, which makes this tool important for scientific works that aim to identify the prevalence of subclinical rumenitis that may indicate the need to improve the management of the diet of confined animals.

## Conflict of interests

The authors declare no conflict of interest.

## Author contributions

*Conceptualization:* P. R. Viana. *Formal analysis:* R. Viana, G. H. M. Araújo and L. F. Viana. *Methodology:* P. R. Viana. *Project management:* P. R. Viana. *Supervision:* P. J. B. Queiroz, D. Q. Cagnini, L. A. F. da Silva and R. E. Rabelo. *Writing (original draft):* I. D. T. de Moraes. *Writing (review and editing):* P. J. B. Queiroz, D. Q. Cagnini, L. A. F. da Silva and R. E. Rabelo.

## References

- Neto JAS, Oliveira VS, Santos ACP, Valença RL. Distúrbios metabólicos em ruminantes- uma revisão. Ver. Bras. Hig. San. Anim. 2014; 8(4): 157-86.
- Vechiato TAF, Maschio W, Bom LC, Lopes PD, Ortolani EL. Estudo retrospectivo de abscessos hepáticos em bovinos abatidos em um frigorífico paulista. Bras. J. Vet. Anim. Sci. 2011; 48(5): 384-91.
- Nagaraja TG, Lechtenberg KF. Liver abscesses in feedlot cattle. Vet. Clin. Food Anim. 2007; 23: 351-69.
- Plaizier JC, Khafipour E, Li S, Gozho GN, Krause DO. Subacute ruminal acidosis (SARA), endotoxins and health consequences. Anim. Feed Sci. Technol. 2012; 172: 9-21.
- Wang DS, Zhang RY, Zhu WY, Mao SY. Effects of subacute ruminal acidosis challenges on fermentation and biogenic amines in the rumen of dairy cows. Livest. Sci. 2013; 155: 262-72.
- Radostits OM, Gay CC, Hinchcliff KW, Constable PD. Veterinary medicine. 3 ed. St. Louis: Elsevier, 2007, 2156p.
- Tadepalli S, Narayanan SK, Stewart GC, Chengappa MM, Nagaraja TG. *Fusobacterium necrophorum*: A ruminal bacterium that invades liver to cause abscesses in cattle. Anaerobe. 2009; 15: 36-43.
- Narayanan S, Nagaraja TG, Okwumabua OGI, Staats J, Chengappa MM, Oberst RD. Ribotyping to compare *Fusobacterium necrophorum* isolates from bovine liver abscesses, ruminal walls, and ruminal contents. Appl. Environ. Microbiol. 1997; 63(12): 4671-78.
- Nocek, JE. Bovine acidosis: implications on laminitis. J Dairy Sci. 1997; 80: 1005-28.
- Owens FN, Secrist DS, Hill WJ, Gill DR. Acidosis in cattle: a review. J. Anim. Sci. 1998; 76: 275-86.
- Habel RE. Sistema digestivo do ruminante. In Getty R, Grossman S. Anatomia dos animais domésticos. Rio de Janeiro: Guanabara Koogan, 1986, 858p.
- Samuelson DA. Tratado de histologia veterinária. Rio de Janeiro: Elsevier, 2007, 544p.
- Brasil. Decreto nº 30.691 de 29 mar 1952. Aprova o novo regulamento da inspeção industrial e sanitária de produtos de origem animal. Ministério da Agricultura, Pecuária e Abastecimento. Diário oficial da União, Brasília (7 jul 1952).
- Tolosa EMC, Rodrigues CJ, Behmer OA, Freitas Neto AG. Manual de técnicas para histologia normal e patológica. Barueri: Manole, 2003, 331p.
- Sampaio IBM. Estatística aplicada à experimentação animal. Belo Horizonte: FEP-MZV, 2007, 265p.
- Nagaraja, TG, Lechtenberg KF. Acidosis in feedlot cattle. Vet. Clin. Food Anim. 2007; 23: 333-50.
- Nagaraja TG. Rumen health. In Simpósio de nutrição de ruminantes – saúde do rúmen. Anais eletrônicos [CD-ROM]. Botucatu: Unesp, 2011.
- Hernández J, Benedito JL, Abuelo A, Castillo C. Ruminal acidosis in feedlot: From aetiology to prevention. Scientific World J. 2014; article ID 702572 [acesso 01 mai 2017]. Disponível em: <http://dx.doi.org/10.1155/2014/702572>
- Steele MA, Croom J, Kahler M, AlZahal O, Hook SE, Plaizer K, McBride BW. Bovine rumen epithelium undergoes rapid structural adaptations during grain-induced subacute ruminal acidosis. Am. J. Physiol. Regul. Integr. Comp. Physiol. 2011; 300: 1515-23.
- Tessele B, Barros CSL. Tumores em bovinos encontrados em abatedouros frigoríficos. Pesq. Vet. Bras. 2016; 36(3): 145-60.
- Bertone AL. Neoplasms of the bovine gastrointestinal tract. Vet. Clin. North Am. Food Anim. Pract. 1990; 6 (2): 515-24.
- Correia WM, Correia CNM. Doenças infecciosas em animais domésticos. São Paulo: Verela, 1992, 843p.
- Valente TNP, Sampaio CB, Lima ES, Deminicis BB, Cezário AS, Santos WBR. Aspects of acidosis in ruminants with a focus on nutrition: a review. J. Agr. Sci. 2017; 9(3): 90-97.
- Rezac DJ, Thomson DU, Bartle SJ, Osterstock JB, Prouty FL, Reinhardt CD. Prevalence, severity, and relationships of lung lesions, liver abnormalities, and rumen health scores measured at slaughter in beef cattle. J. Anim. Sci. 2014; 92: 2595-602.
- Smith HA. Ulcerative lesions of the bovine rumen and their possible relation to hepatic abscess. Am. J. Vet. Res. 1944; 5: 234-42.
- Costa SF, Pereira MN, Melo LQ, Caliarri MV, Chaves ML. Alterações morfológicas induzidas por butirato, propionato e

lactato sobre a mucosa ruminal e epiderme de bezerros. II. Aspectos ultra-estruturais. Arq. Bras. Med. Vet. Zootec. 2008; 60(1): 10-18.

27. Xu Y, Ding Z. Physiological, biochemical and histopathological effects of fermentative acidosis in ruminant production: a minimal review. Span J Agric Res. 2011; 9(2): 414-22.

28. González LA, Manteca X, Calsamiglia S, Schwartzkopf GKS, Ferret A. Ruminal acidosis in feedlot cattle: Interplay

between feed ingredients, rumen function and feeding behavior. Anim. Feed Sci. Technol. 2012; 172: 66-79.

29. Borges, J.R.J. et al. Doenças dos dígitos dos bovinos: nomenclatura padronizada para o Brasil. Revista CFMV, Brasília, v.23, n.73, p.45-72, abr./jun. 2017.

30. Egger-Danner et al. ICAR claw health atlas. [https://www.icar.org/ICAR\\_Claw\\_Health\\_Atlas.pdf](https://www.icar.org/ICAR_Claw_Health_Atlas.pdf), 2020.