

Morphometry and skeletopy of kidneys and renal vessels in "ring-tailed coati" (*Nasua nasua*)

Morfometria e esqueletopia dos rins e vasos renais no "quati de cauda anelada" (Nasua nasua)

Rafaela Dünkel Duarte¹ , Shirley Viana Peçanha¹ , Thais Mattos Estruc¹ , Renata Medeiros do Nascimento¹ , Carlos Augusto Santos Sousa^{2*} , Paulo Souza Júnior³ , Marcelo Abidu-Figueiredo¹ 

¹Universidade Federal Rural do Rio de Janeiro (UFRRJ), Seropédica, Rio de Janeiro, Brazil

²Universidade Federal do Acre (UFAC), Rio Branco, Acre, Brazil

³Universidade Federal do Pampa (UNIPAMPA), Uruguaiana, Rio Grande do Sul, Brazil

*Correspondent: carlos.sousa@ufac.br

Abstract

Nasua nasua is a carnivore belonging to the family Procyonidae and is widely distributed throughout South America. The details of its anatomy are fundamental to the application of anatomy and understanding of its natural history. This study aimed to measure the average length, width, thickness, and volume of the kidneys; the average length of the renal artery and vein, and to describe the renal and vessel skeletopy in *Nasua nasua*. For this purpose, 32 kidneys and renal vessels of 16 cadaveric specimens (eight male and eight female) were dissected and measured using a digital caliper. Pearson's correlation coefficients were calculated between the rostrum-sacral length and the renal and vessel variables. The kidneys had a "bean-shaped" aspect with smooth surfaces and were unipapillate. On average, the *N. nasua* kidneys measured $30 \times 16 \times 13$ mm, with no significant difference between the sexes. The average right renal artery (1.74 ± 0.67 cm) was longer than the left (1.26 ± 0.43 cm), and the right renal vein (1.22 ± 0.34 cm) was shorter than the left renal vein (1.82 ± 0.46 cm) ($p < 0.05$). One male animal (6.8%) presented with a double right renal vein as an anatomical variation. Both the right and left kidney cranial poles prevailed at the level of the L2 vertebra, assuming a practically symmetrical position. There was a positive and moderate to high correlation between rostrum-sacral length and renal dimensions and renal vessel lengths. The present data may be useful for interpreting the diagnosis of nephropathies that affect renal dimensions in this species and may contribute to the comparative anatomy of carnivorans.

Keywords: Neotropical carnivorans; Nephrology; South American coati; Vascularization; Wild carnivores

Resumo

Nasua nasua é um carnívoro da família Procyonidae amplamente distribuído pela América do Sul. Detalhes de sua anatomia são fundamentais para a anatomia aplicada e o entendimento de sua história natural. Objetivou-se determinar a média do comprimento, largura, espessura e volume elipsoide dos rins, a média do comprimento das artérias e veias renais e revelar a esqueletopia dos rins e vasos renais em *N. nasua*. Para este propósito, 32 rins e os vasos renais de 16 espécimes cadavéricos (oito machos e oito fêmeas) foram dissecados e mensurados com um paquímetro digital. Os coeficientes de correlação linear de Pearson foram calculados entre o comprimento rostro-sacral e as variáveis dos rins e seus vasos. Os rins apresentaram formato de "feijão" e superfícies lisas e são unipapilados. Na média, os rins de *N. nasua* mediram $30 \times 16 \times 13$ mm, sem diferença significativa entre antímeros ou sexos. O comprimento médio da artéria renal direita ($1,74 \pm 0,67$ cm) foi maior que o da esquerda ($1,26 \pm 0,43$ cm); o comprimento da veia renal direita ($1,22 \pm 0,34$ cm) foi menor que o da esquerda ($1,82 \pm 0,46$ cm) ($p < 0,05$). Em um macho (6,8%), foi identificada uma veia renal direita dupla como variação anatômica. Os polos craniais dos rins direito e esquerdo prevaleceram ao nível da vértebra L2, assumindo praticamente uma posição simétrica. Houve uma correlação positiva, moderada a elevada, entre o comprimento rostro-sacral com as dimensões renais e com o comprimento dos vasos renais. Os dados do presente estudo poderão vir a ser aplicados na interpretação do diagnóstico de nefropatias que cursam com alterações nas dimensões renais bem como contribuir no campo da anatomia comparada de carnívoros.

Palavras-chave: quati; carnívoros neotropicais; carnívoros selvagens; nefrologia

Recebido : March 24, 2022. Aceito: May12, 2022. Publicado: July 7, 2022.



Introduction

Morphological studies regarding *Nasua nasua* ("ring-tailed coati") are exciting tasks since they contribute to comprehending ecological traits from a species distributed over practically the entire South American continent. Furthermore, anatomy, one of the oldest biomedical sciences, is a crucial tool for resolving issues regarding the biology and evolution of species, especially concerning interactions involving the habitat environment, feeding, and reproductive adaptations. In addition, the morphology of anatomical structures reveals the natural history of a species ⁽¹⁾.

Nasua nasua (Linnaeus, 1766) is found widely throughout South America and predominantly inhabits Brazil's Atlantic Forest, Amazon Rainforest, and Pantanal regions ⁽²⁾. They belong to the order Carnivora and family Procyonidae. This family is subdivided into two subfamilies: Procyoninae and Ailurinae. The representatives of the subfamily Procyoninae include six genera; in South America, there are only the genera *Nasua*, *Procyon*, *Potos*, and *Bassaricyon* ⁽³⁾.

In domestic dogs, the kidneys are bean-shaped and retroperitoneally positioned against the sublumbar muscles. The usual position of the right kidney is ventral to the first three lumbar vertebrae; the left kidney is ventral to the second to fourth lumbar vertebrae, although they may be observed more caudally. The right kidney is more settled because it is deeply recessed within the liver and medially related to the right adrenal gland and caudal vena cava, laterally to the last rib and abdominal wall, and ventrally to the liver and pancreas. The left kidney is cranially related to the spleen (or stomach when enlarged), medially to the left adrenal gland and aorta, laterally to the abdominal wall, and ventrally to the descending colon ⁽⁴⁾.

The kidneys of domestic cats are relatively large and have a distinctive appearance with capsular veins converging over the surface toward the hilus. They are more mobile than the kidneys of dogs, and the left kidney can be displaced cranially or caudally from their usual position below the second to fifth lumbar vertebrae. Both kidneys are palpable in cats ⁽⁴⁾.

Each kidney has a cranial and caudal pole, medial and lateral borders, and dorsal and ventral surfaces. The convex lateral border joins the cranial and caudal poles. The medial border has an indentation (hilus) that defines the renal sinus. The sinus contains the ureter, renal artery, renal vein, lymph vessels, and nerves. Of these structures, the renal artery is the most dorsal and the renal vein is the most ventral. Typically, the renal vein is paired on one or both sides, and sometimes the renal artery may also be paired ⁽⁵⁾. Usually, in most species, the right renal artery is more cranial than the left, per the relatively more cranial position of the right kidney ⁽⁶⁾.

Knowledge of average renal measures may help diagnose different kidney diseases. Variations in these measures can occur in nephropathies owing to hypertrophic processes and/or atrophy ⁽⁷⁾. Therefore, it is imperative to establish a pattern of typical renal measures for each species. It has been postulated from human necropsy studies that variations in renal dimensions and weight are related to gender, being higher in males. The left kidney is known to be larger than the right kidney regardless of sex ⁽⁸⁾. However, this information is scarce for wild animals.

Despite an increase in basic and applied research involving wild animals, anatomical studies describing renal anatomy and vascularization in these species are scarce. However, concerning morphology, a small number of studies concerning these species have shown that it is crucial to obtain anatomical information both for future work and for preserving the species in captivity or in natural habitats. Therefore, this study determined the morphometric variables of the kidneys and renal vessels in *N. nasua* and compared the data, with an emphasis on the order Carnivora.

Materials and methods

This study was approved by the Research Ethics Committee of Federal Rural University of Rio de Janeiro (018/2017). Anatomical dissections were performed on 16 adult ring-tailed coatis cadavers without visible signs of renal pathology: 8 males and 8 females with a rostrum-sacral length of 35.38 ± 9.620 cm and 35.56 ± 5.500 cm, respectively. Specimens were obtained from the Laboratory of Teaching and Research in Morphology of Domestic and Wild Animals collection of the Department of Animal and Human Anatomy, Federal Rural University of Rio de Janeiro.

For fixation of the specimens, the thorax was first opened and dissected, and urethral catheter number 6 was introduced into the thoracic aorta. The arterial system was then "washed" with 0.9% NaCl solution and the cadaver was fixed with 10% formalin solution. Next, an aqueous solution (1:1 dilution) of Petrolátex S-65 (Refinery Duque de Caxias-REDUC-Petrobras, Duque de Caxias-RJ) was injected together with a dye (Xadrez®). Finally, the specimens were immersed in a 500 L low density polyethylene box containing 10% formaldehyde solution to complete the latex fixation and polymerization processes. At least seven days after latex injection, the cadavers were washed in running water, and their peritoneal cavities were opened and dissected to demonstrate the kidneys, their respective vessels, and skeleton. Renal measurements (length, width, and thickness) were obtained using a digital caliper (0–150 mm, 0.01 mm resolution, accuracy ± 0.02 mm).

The ellipsoid volume of each kidney was

estimated according to Sampaio⁽⁹⁾ (1995). The length and origin of the renal arteries and main branches, and the length of the renal veins were also determined. The mean and standard deviation of kidney and renal vessel measurements were calculated and compared between the sexes using unpaired Student's *t*-test. A Chi-square (χ^2) test was performed to test the null hypothesis for skeletopy of the right and left kidneys. Pearson's correlation coefficient ($-1 < r < 1$) estimated the relationship between the renal measures and the rostrum-sacral length. Differences were considered statistically significant at $P < 0.05$. Data were analyzed using GraphPad Prism 5 software.

Results

Gross anatomy

Both kidneys were symmetrical in shape and presented a format that resembles a "bean seed." They were brownish, pale, smooth on their surface, and devoid of lobations. The kidneys consisted of an outer renal cortex and an inner medulla, with the pelvis and renal crest in the longitudinal and transverse sections. They were simple and unipapillary (Figures 1 and 2).

The average measurements of the left and right kidneys of the coatis did not differ, despite significant antimeric differences in the lengths of the renal arteries and veins (Table 1).

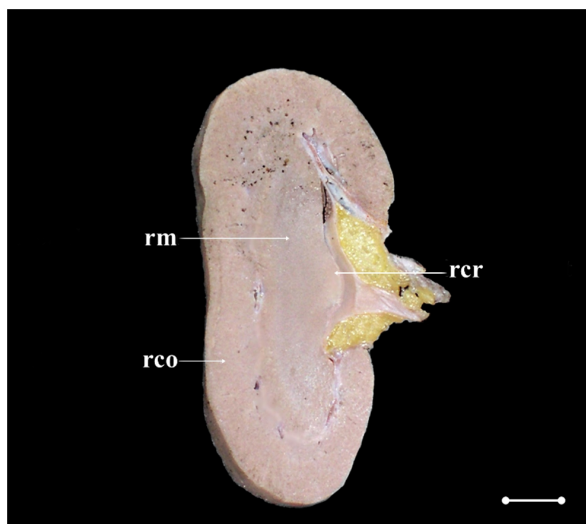


Figure 1. Digital photomicrography of a longitudinal section of the left kidney from a male specimen of *N. nasua*. rm, renal medulla; rco, renal cortex; rcr, renal crest. Scale bar: 1.0 cm.

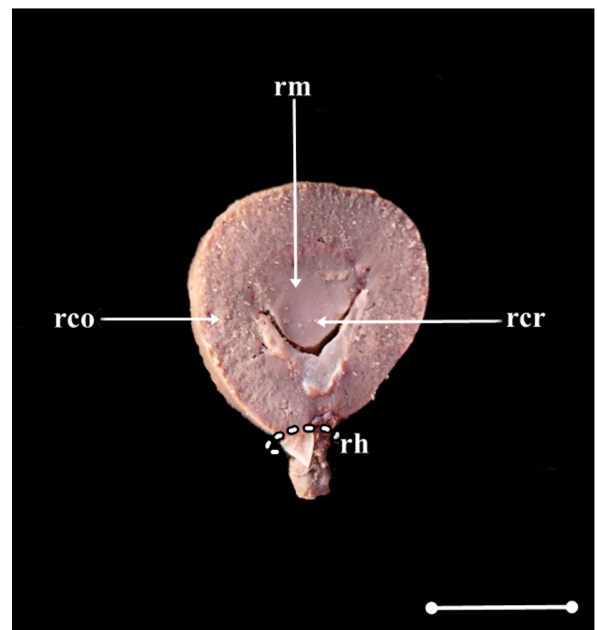


Figure 2. Digital photomicrography of a transversal section of the left kidney from a male specimen of *N. nasua*. rm, renal medulla; rco, renal cortex; rcr, renal crest; rh, renal hilum. Scale bar: 1.0 cm.

Table 1. Average \pm standard deviation of renal and vessel measurements (cm) in *N. nasua* (n = 16). The P-value was calculated using Student's *t*-test and compared to the average between antimers

	<i>N. nasua</i> (n = 16)		
	Right	Left	P-value
Renal length	2.93 \pm 0.47	3.02 \pm 0.52	0.60
Renal width	1.63 \pm 0.23	1.58 \pm 0.19	0.49
Renal thickness	1.37 \pm 0.19	1.38 \pm 0.28	0.88
Ellipsoid Volume (cm ³)	3.56 \pm 1.51	3.60 \pm 1.68	0.94
Renal artery length	1.74 \pm 0.67	1.26 \pm 0.43	0.02*
Renal vein length	1.22 \pm 0.34	1.83 \pm 0.47	< 0.01*

*significantly different ($p < 0.05$).

Average measurements of kidneys and renal vessels did not differ between sexes (Table 2).

The skeleton of the right kidney cranial pole prevailed at the L2 or L3 level in 68.8% of samples. In addition, the left kidney cranial pole predominated at L2 or caudally in 56.3% of the animals (Table 3).

Table 2. Average \pm standard deviation of renal and vessels measurements (cm) in *N. nasua* (n = 16), separated by sexes. P-values were calculated using Student's *t*-test and compared to the averages between sexes

	<i>Nasua nasua</i>			
	Males (n = 8)	Females (n = 8)	P-value	General (n = 16)
Length of the right kidney	2.83 \pm 0.37	3.03 \pm 0.56	0.41	2.93 \pm 0.47
Length of the left kidney	2.99 \pm 0.51	3.05 \pm 0.57	0.84	3.02 \pm 0.52
Width of the right kidney	1.53 \pm 0.15	1.73 \pm 0.25	0.07	1.63 \pm 0.22
Width of the left kidney	1.53 \pm 0.01	1.63 \pm 0.25	0.30	1.58 \pm 0.19
Thickness of the right kidney	1.31 \pm 0.18	1.42 \pm 0.20	0.24	1.37 \pm 0.19
Thickness of the left kidney	1.37 \pm 0.32	1.39 \pm 0.25	0.84	1.38 \pm 0.28
Ellipsoid volume of the right kidney (cm ³)	3.03 \pm 0.99	4.09 \pm 1.80	0.16	3.56 \pm 1.51
Ellipsoid volume of the left kidney (cm ³)	3.37 \pm 1.46	3.83 \pm 1.95	0.60	3.60 \pm 1.68
Length of the right renal artery	1.76 \pm 0.78	1.72 \pm 0.58	0.90	1.74 \pm 0.67
Length of the left renal artery	1.15 \pm 0.48	1.38 \pm 0.38	0.31	1.26 \pm 0.43
Length of the right renal vein	1.11 \pm 0.38	1.34 \pm 0.28	0.19	1.22 \pm 0.34
Length of the left renal vein	1.84 \pm 0.50	1.81 \pm 0.46	0.90	1.82 \pm 0.46

*significantly different (P < 0.05).

Table 3. Absolute (AF) and Simple percentage (SPF) frequencies of right and left kidney skeletopy in *N. nasua* (n = 16), separated by sexes

Skeletopy	Males (n = 8)				Females (n = 8)			
	Right		Left		Right		Left	
	AF	SPF	AF	SPF	AF	SPF	AF	SPF
L1 - L2	2	25%	-	-	1	12.5%	-	-
L2 - L3	1	12.5%	2	25%	2	25%	2	25%
L3 - L4	-	-	1	12.5%	-	-	-	-
L4 - L5	-	-	-	-	-	-	1	12.5%
L1 - L3	2	25%	4	50%	-	-	3	37.5%
L2 - L4	3	37.5%	1	12.5%	4	50%	1	12.5%
L3 - L5	-	-	-	-	1	12.5%	1	12.5%

The average rostrum-sacral length was 35.47 \pm 7.57 cm (n = 16), being 35.38 \pm 9.62 cm in males (n = 8) and 35.56 \pm 5.49 cm in females (n = 8), without statistically significant differences (P = 0.96). When considering the whole sample (n = 16), the rostrum-sacral length was positively and significantly correlated with right and left renal lengths, renal volumes, renal

artery lengths, and renal vein lengths (Table 4), except for left renal artery length. On the other hand, the coefficients calculated separately by sex still demonstrated a positive correlation between these measurements but were not always statistically significant (Tables 5 and 6).

Table 4. Pearson's correlation coefficient ("r") between the rostrum-sacral length (RSL) and renal length and volume, and vessel lengths in *N. nasua* (n = 16)

<i>N. nasua</i> (n = 16)	Right		Left	
	r	P-value	r	P-value
RSL × Kidney length	0.68	0.0041*	0.80	0.0002*
RSL × Renal artery length	0.69	0.0030*	0.41	0.1189
RSL × Renal vein length	0.71	0.0022*	0.62	0.0110*
RSL × Kidney Ellipsoid Volume (cm ³)	0.57	0.0214*	0.71	0.0021*

*significantly different (P < 0.05).

Table 5. Pearson's correlation coefficient ("r") between the rostrum-sacral length (RSL) and renal length and volume, and vessels lengths in male *N. nasua* (n = 8)

Males (n = 8)	Right		Left	
	r	P-value	r	P-value
RSL × kidney length	0.70	0.0528	0.88	0.004*
RSL × Renal artery length	0.78	0.0227*	0.45	0.2652
RSL × renal vein length	0.84	0.0095*	0.63	0.0939
RSL × kidney ellipsoid volume (cm ³)	0.61	0.1083	0.84	0.0088*

*significantly different (P < 0.05).

Table 6. Pearson's correlation coefficient ("r") between the rostrum-sacral length (RSL) and renal length and volume, and vessels lengths in female *N. nasua* (n = 8)

Females (n = 8)	Right		Left	
	r	p-value	r	p-value
RSL × kidney length	0.85	0.0076*	0.78	0.0236*
RSL × renal artery length	0.51	0.1982	0.37	0.3738
RSL × renal vein length	0.57	0.1424	0.64	0.0874
RSL × kidney ellipsoid volume (cm ³)	0.81	0.0155*	0.69	0.0565

*significantly different (P < 0.05).

Renal vessels

The average length of the right renal artery (1.74 ± 0.67 cm) was significantly greater than that of the left renal artery (1.26 ± 0.43 cm). In all males (n = 08) and females (n = 8), the renal arteries were dissected and emerged directly from the abdominal aorta as a single vessel (Figure 3).

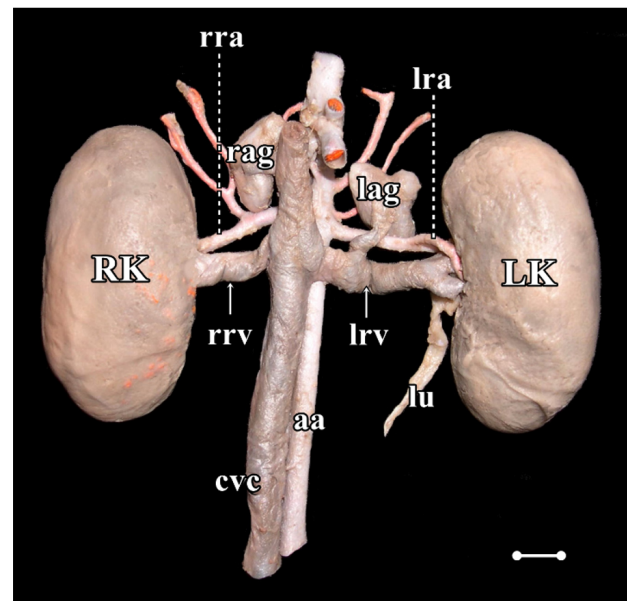


Figure 3. Digital photomicrography of the ventral view of both kidneys and renal vessels from a male specimen of *N. nasua*. aa, aorta artery; cvc, caudal vena cava; LK, left kidney; lag, left adrenal gland; lra, left renal artery; lrv, left renal vein; lu, left ureter; RK, right kidney; rag, right adrenal gland; rra, right renal artery; rrv, right renal vein; Scale bar: 1.0 cm.

The right renal artery emerged at the level of L1 in 12.5% of males, between L1 and L2 in 12.5%, L2 in 62.5%, and L3 in 12.5%. The left renal artery emerged at the level of L1 in 12.5% of males, L2 in 50%, between L2 and L3 in 12.5%, and L3 in 25%.

In females, the right renal artery emerged at the level of L1 in 12.5%, L2 in 25%, between L2 and L3 in 25%, and L3 in 37.5%. The left renal artery emerged at the L2 (62.5%), L3 (25%), and L4 (12.5%) levels. The renal arteries issued branches to the ipsilateral adrenal gland and the ureter.

Veins

The average length of the right renal vein (1.22 ± 0.34 cm) was significantly less than that of the left renal vein (1.82 ± 0.46 cm). The renal vein was a single vein in 15 animals (93.8%); however, one male specimen had a duplicated right renal vein (6.2%).

In males, the right renal vein drained into the caudal vena cava at the level of L1 and L2 in 12.5%, L2 in 62.5%, and L3 in 25%. The left renal vein addressed the caudal vena cava at the level of L1 and L2 in 12.5%, L2 in 50%, L2 and L3 in 12.5%, and L3 in 25% of male coatis.

In females, the right renal vein drained into the caudal vena cava at the level of L1 in 12.5%, L2 in 25%,

between L2 and L3 in 25%, and L3 in 37.5%. The left renal vein emerged at the level of L2 and L3 in 62.5% and L3 in 37.5% of female specimens.

Discussion

Renal measurements and skeletopy

On average, the kidneys of *N. nasua* measured approximately $30 \times 16 \times 13$ mm; thus, these are smaller than the kidneys of most carnivorans. The kidneys of the domestic dog are approximately $60\text{--}90 \times 40\text{--}50 \times 30 \times 40$ mm⁽⁵⁾, *Lycalopex gymnocercus* $45 \times 24 \times 21$ mm⁽¹⁰⁾, *Cerdocyon thous* $43\text{--}55 \times 21\text{--}29 \times 18\text{--}30$ mm⁽¹¹⁾, and domestic cats ($38 \times 24 \times 23$ mm)⁽¹²⁾. Among the described species, only *Mustela putorius furo* has average kidney dimensions ($24\text{--}30 \times 12\text{--}13.5 \times 11 \times 13.5$ mm)⁽¹³⁾ close to those of *N. nasua*. As a consequence, the average ellipsoid volume of *N. nasua* kidneys (3.6 cm³) is also smaller than *C. thous* (14–16 cm³)⁽¹¹⁾, *L. gymnocercus* (11–12 cm³)⁽¹⁰⁾, and domestic cat (9–12 cm³)⁽¹²⁾.

These differences in renal measurements between carnivorans may correlate with body size of the species. In fact, all renal measurements were positively and significantly correlated with rostrum-sacral length in *N. nasua* ($r > 0.5$, and $P < 0.05$). The same has been reported for the ellipsoid volume in domestic cats⁽¹²⁾.

Renal measurements are relevant to clinical decisions and serve as surrogates for renal functional reserve⁽¹⁴⁾. In addition, morphometric values provide indirect clues regarding renal disease progression and stability. Unfortunately, there is a lack of information regarding the kidney sizes of species commonly cared for in wild animal medicine. Among the common kidney diseases in the wild, dirotyphimiasis can affect *N. nasua*⁽¹⁵⁾.

The set of renal dimensions reported in this study serves as a preliminary parameter for interpreting imaging findings and necropsy in *N. nasua*. However, these data must be cautiously applied because the body size of one particular specimen might result in a normal kidney with higher or lower dimensions than those proposed in our study. For example, in *C. thous* individuals, the kidneys of the southern population were significantly larger, probably because of different body sizes and diets⁽¹¹⁾. Furthermore, the present sample of coatis provided data from free-living young adults, whereas captive animals certainly have a different diet and are more long-lived. Furthermore, anthropogenic interactions may include coatis prone to obesity⁽¹⁶⁾. An abdominal ultrasound study in seven *N. nasua*⁽¹⁷⁾ revealed kidney dimensions ($3.0 \times 1.8 \times 1.6$ cm) very close to our data, confirming the reliability of the morphometric base. These aspects must be considered when interpreting our findings.

Despite the strong correlation between renal

dimensions and body size in *N. nasua*, there were no differences in kidney measures between the sexes. One explanation is that rostrum-sacral lengths were similar between males and females ($P > 0.05$) in our sample. However, biometric reports indicate that male coatis are generally larger^(16,18). *L. gymnocercus*⁽¹⁰⁾ and *C. thous*⁽¹¹⁾ are other examples of carnivorans in which renal dimensions do not differ between sexes. Nonetheless, a number of imaging studies have suggested that the kidneys of male dogs are significantly larger^(19–22).

As reported in *C. thous*⁽¹¹⁾, *L. gymnocercus*⁽¹⁰⁾, and domestic dogs⁽²¹⁾, the renal dimensions did not differ between antimeres in *N. nasua*. However, in domestic cats, only males have larger left kidneys⁽¹²⁾.

The "bean-shaped" or ovoid kidneys observed in *N. nasua* represent a trait observed in other carnivorans such as domestic dogs⁽⁵⁾ and cats⁽¹²⁾, *L. gymnocercus*⁽¹⁰⁾, *C. thous*⁽¹¹⁾ and *M. p. furo*⁽¹³⁾. However, bean-shaped kidneys are not synapomorphic in Carnivora species. For example, *Lontra* has an elliptical multilobular kidney that presents lobes at the organ surface⁽²³⁾. In addition, an abdominal ultrasound study revealed an oval shape of *N. nasua* kidneys⁽¹⁷⁾.

The skeleton of the cranial pole of the right kidney prevailed caudally or at the L2 level (68.5%), whereas the cranial pole of the left kidney predominated caudally or at the L2 level (56.3%). With the cranial pole at the level of L2 or caudally, both kidneys may be, at least partially, identified on abdominal palpation during clinical examination. Based on skeletal data, the right and left kidneys are considered practically at the same vertebral level, although an abdominal ultrasound study suggested that the right kidney is slightly cranial in *N. nasua*⁽¹⁷⁾. This symmetric positioning at the same vertebral level differs from previous reports in other carnivorans. *C. thous*⁽¹¹⁾, domestic dogs⁽⁵⁾ and cats⁽¹²⁾, and *M. p. furo*⁽¹³⁾ have the right kidney usually cranial to the left, similar to other wild mammals such as *Didelphis albiventris*⁽²⁴⁾. A cranially positioned right kidney is also prevalent among domestic ungulates, other than pigs⁽²⁵⁾.

Renal vessels

In *N. nasua* the right renal artery is longer than the left artery, and the left renal vein is longer than the right vein. This confirmed our expectations because the abdominal aorta is positioned slightly to the left and the caudal vena cava to the right of the median plane. However, the right renal artery is not longer in *C. thous*⁽¹¹⁾, *L. gymnocercus*⁽¹⁰⁾, and domestic felines⁽¹²⁾. As in coatis, the left renal vein is longer in domestic dogs⁽⁵⁾, *L. gymnocercus*⁽¹⁰⁾, *C. thous*⁽¹¹⁾, and domestic cats⁽¹²⁾.

One male specimen had a duplicated right renal vein. Observation of the double renal vein has been reported in domestic dogs as being as rare as 1%, but also restricted to the right vein^(26,27). Double and triple right

renal veins have been described in domestic^(28,29) and wild carnivorans, such as *Leopardus pardalis*⁽³⁰⁾, *Leopardus tigrinus*⁽³¹⁾, and *Puma concolor*⁽³²⁾. Therefore, variation in the number of renal vessels, especially the double right renal veins, must be considered in planning kidney surgery for carnivorans.

Conclusion

The kidneys of *N. nasua* have a shape similar to that of most other carnivoran species; however, the right and left kidneys are symmetrical inside the cavity. Furthermore, *N. nasua* kidneys did not differ between the sexes. Our data may serve as a basis to recognize an enlarged or reduced kidney during wild animal medical procedures; however, the positive and strong correlation of the dimensions of the kidneys with the individual body size must also be considered.

Declaration of conflict of interest

The authors declare that they have no competing interest.

Author Contributions

Data curation: R.D. Duarte and S.V. Peçanha; *Formal analysis:* T. M. Estruc and R. M. Nascimento; *Research:* R.D. Duarte and S.V. Peçanha; *Methodology:* R.D. Duarte, S.V. Peçanha, T. M. Estruc and R. M. Nascimento; *Resources:* M. A. Figueiredo; *Supervision:* C. A. Santos-Sousa, P. Souza-Júnior and M. A. Figueiredo; *Validation:* C. A. Santos-Sousa, P. Souza-Júnior and M. A. Figueiredo; *Visualization:* T. M. Estruc and R. M. Nascimento; *Writing (original draft):* M. A. Figueiredo; *Writing (review and editing):* C. A. Santos-Sousa and P. Souza-Júnior. All authors read and approved the final manuscript version.

Acknowledgments

This study was financed in part by National Council of Technological and Scientific Development (CNPq), Rio de Janeiro State Research Foundation (FAPERJ) and Coordination of Superior Level Staff Improvement (CAPES) Finance Code 001.

References

- Assunção MPB, Oliveira TAD, Oliveira, TS, Oliveira, LP, Silva DCO, Barros RAC, Silva Z. Comparative anatomy of abdominal aorta in coati (*Nasua nasua*). International Journal of Advanced Engineering Research and Science. 2019;6:259-267. Available from: <https://doi.org/10.22161/ijaers.6.2.32>
- Trovati GR, Brito BA, Duarte JMB. Habitat use and home range of brown-nosed coati. (*Nasua nasua*) Carnivora: Procyonidae in the Brazilian cerrado biome. Revista de Biologia Tropical. 2010;58:1069–1077.
- Santos VA, Beisiegel BM. A dieta de *Nasua nasua* (Linnaeus, 1766) no Parque Ecológico do Tietê. SP. Revista Brasileira de Zootecias. 2006; 8:195-198.
- Dyce KM, Sack WO, Wersing CJG. Tratado de Anatomia Veterinária, 5th edition. Rio de Janeiro: Elsevier, 2019.

- Evans HE, DeLahunta A. Miller's Anatomy of the Dog. 4th edition. St Louis (MO): Saunders Elsevier, 2013.
- Nickel RA, Schummer E, Seiferle. The anatomy of the domestic animals Berlin: Verlag Paul Parey, 1981.
- Elkin. M. Kidney size. In: _____ (Ed.). Radiology of the urinary system. Boston: Little. Brown and Company, 1980. p.1014-1032.
- Moell. H. Size of normal kidneys. Acta radiologica. 1956;46:640-5.
- Sampaio FJ. Theoretical kidney volume versus real kidney volume: comparative evaluation in fetuses. Surgical and Radiologic Anatomy. 1995;17:71-75. Available from: <https://doi.org/10.1007/bf01629504>
- Souza EC, Leao Neto LF, Santos EAR, Abidu-Figueiredo M, Carvalho AD, Souza Junior P. Caracterización anatómica de los riñones del Zorro Pampeano (*Lycalopex gymnocercus*): morfometría y vasos renales. Revista Electrónica de Veterinaria. 2018;19:1-8.
- Souza-Junior P, Souza EC, Viana-Peçanha S, Bernardes FCS, Montana MM, Abidu-Figueiredo M. Dimensions and skeletopy of kidneys in two populations of *Cerdocyon thous* (Linnaeus, 1766). Acta Veterinaria Brasílica. 2020;14:106-114. Available from: <https://doi.org/10.21708/avb.2020.14.2.9126>
- Stocco AV, Sousa CAS, Gomes MS, Souza Junior P, Abidu-Figueiredo M. Is there a difference between the right and left kidney? A macroscopic approach in Brazilian Shorthair Cat. Arquivo Brasileiro de Medicina Veterinária e Zootecnia. 2016;68:1137-1144. Available from: <https://doi.org/10.1590/1678-4162-8339>
- Evans H, An NQ. Anatomy of the ferret. In: Fox JG, Marini RP. Biology and Diseases of the Ferret. 3rd edition. Oxford (UK): Wiley Blackwell, 2014. p. 23–68.
- Moorthy HK, Venugopal P. Measurement of renal dimensions in vivo: A critical appraisal. Indian Journal of Urology. 2011;27:169-175. Available from: <https://doi.org/10.4103/0970-1591.82832>
- Milanelo L, Moreira MB, Fitorra LS, Petri BSS, Alves M, Santos AC. Occurrence of parasitism by *Diocotophyma renale* in ring-tailed coatis (*Nasua nasua*) of the Tiete Ecological Park, São Paulo, Brazil. Pesquisa Veterinaria Brasileira. 2009;29:959-962. Available from: <https://doi.org/10.1590/S0100-736X2009001200001>
- Ferro BS, Hippólito AG, Castiglioni MCR, Junior JIDSS, Teixeira CR, Gonçalves RAB, Melchert A. Medidas biométricas, avaliação do escore corporal e índice de massa corpórea em Quatis (*Nasua nasua*) de vida livre da região Centro Sul do estado de São Paulo, Brasil. Acta Scientiae Veterinariae. 2019;47: 1639-45.
- Ribeiro RG, Costa APA, Bragato N, Fonseca AM, Duque JCM, Prado TD, Silva ACR, Borges NC. Normal sonographic anatomy of the abdomen of coatis (*Nasua nasua* Linnaeus 1766). BMC Veterinary Research. 2013;9:124-134. Available from: <https://doi.org/10.1186/1746-6148-9-124>
- Gompper ME, Decker DM. *Nasua nasua*. Mammalian Species 1998; 580: 1–9. Available from: <https://doi.org/10.2307/3504444>
- Lobacz MA, Sullivan M, Mellor D, Hammond G, Labryère J, Dennis R. Effect of breed, age, weight and gender on radiographic renal size in the dog. Veterinary Radiology and Ultrasound. 2012;53:437-441. Available from: <https://doi.org/10.1111/j.1740-8261.2012.01937.x>
- Mareschal A, d'Anjou MA, Moreau M, Alexander K, Beau-

- regard G. Ultrasonographic measurement of kidney-to-aorta ratio as a method of estimating renal size in dogs. *Veterinary Radiology and Ultrasound*. 2007;48:434-438. Available from: <https://doi.org/10.1111/j.1740-8261.2007.00274.x>
21. Sampaio KMOR, Araújo RB. Ultrassonografia de características lineares e estimativas do volume de rins de cães. *Arquivo Brasileiro de Medicina Veterinária e Zootecnia*. 2002;54:248-254. Available from: <https://doi.org/10.1590/S0102-09352002000300005>
22. Sohn J, Yun S, Lee J, Chang D, Choi M, Yoon J. Reestablishment of radiographic kidney size in Miniature Schnauzer dogs. *Journal of Veterinary Medical Science*. 2016;78:1805-1810. Available from: <https://doi.org/10.1292/jvms.16-0003>
23. Baitchman, EJ, Kollias, GV. Clinical anatomy of the North American river otter (*Lontra canadensis*). *Journal of Zoo and Wildlife Medicine*. 2000;31:473-483. Available from: [https://doi.org/10.1638/1042-7260\(2000\)031\[0473:caotna\]2.0.co;2](https://doi.org/10.1638/1042-7260(2000)031[0473:caotna]2.0.co;2)
24. Peçanha SV, Dünkel-Duarte R, Bernardes FCS, Estruc TM, do Nascimento RM, Dos Santos-Sousa CA, de Souza Junior P, Abidu-Figueiredo M. Anatomical characterization of the kidneys of *Didelphis aurita* (Didelphimorphia: Didelphidae). *Folia Morphologica*. 2020; 5:805-810. Available from: <https://doi.org/10.5603/FM.a2020.0006>
25. König HE, Maierl J, Liebich HG. Systema urinarium. In: König HE, Liebich HG. *Veterinary Anatomy of Domestic Animals*, 6th edition, New York, NY: Schattauer. 2016. p. 399-410.
26. Reis RH, Tepe P. Variations in the pattern of renal vessels and their relation to the type posterior vena cava in the dog (*Canis familiaris*). *American Journal of Anatomy*. 1956; 99:1-15. Available from: <https://doi.org/10.1002/aja.1000990102>
27. Fagundes GM, Souza A, Borelli V, Riella ACM. Contribuição ao estudo da drenagem sanguínea do rim de cães (*Canis familiaris* – Linnaeus, 1758). *Biotemas*. 1990;3:117-127.
28. Campos CBA, Rocha OS, Abidu-Figueiredo M. Veia renal dupla em gatos: relato de casos. *Revista Acadêmica de Ciências Agrárias e Ambientais*. 2014;12:127-131. Available from: <https://doi.org/10.7213/academica.12.02.AO06>
29. Stocco AV, Stocco NV, Santos-Sousa CA, Abidu-Figueiredo M. Veia renal tripla em gato: relato de casos. *Revista Portuguesa de Ciências Veterinárias*. 2014;109:120-122.
30. Stocco AV, Silva SC, Toledo KS, Sousa CAS, Carvalho RBJ, Abidu-Figueiredo M. Veia renal direita dupla em jaguatirica (*Leopardus pardalis*): relato de caso. *Revista Portuguesa de Ciências Veterinárias*. 2017;112:83-86.
31. Stocco AV, Silva SC, Toledo KS, Sousa CAS, Carvalho RBJ, Abidu-Figueiredo M. Duplicidade da veia renal direita em gato-mato-pequeno (*Leopardus guttulus*): relato de caso. *Revista Acadêmica de Ciência Animal*. 2018;16:1-6.
32. Stocco A, Oliveira R, Santos-Sousa CA, Júnior P, Abidu-Figueiredo M. Duplicity of the right renal vein in *Puma concolor* (Carnivora: Felidae): a case report. *Acta Scientiae Anatomica* 2018;1:29-32.