

# UTILIZATION OF THE AQUEOUS EXTRACT OF *Triticum vulgare* (BANDVET®) AFTER SUPERFICIAL KERATECTOMY IN DOMESTIC CATS AFFLICTED WITH CORNEAL SEQUESTRUM

PAULA DINIZ GALERA,<sup>1</sup> MÁRIO SÉRGIO ALMEIDA FALCÃO,<sup>2</sup> CÁSSIO RICARDO RIBEIRO,<sup>3</sup> ANA CATARINA VIANA VALLE<sup>4</sup> E JOSÉ LUIZ LAUS<sup>5</sup>

1. Professora adjunto II da Faculdade de Agronomia e Medicina Veterinária, Universidade de Brasília, DF. E-mail: paulaeye@unb.br

2. Mestrando do Programa de Pós-Graduação em Saúde Animal, Faculdade de Agronomia Veterinária, Universidade de Brasília, DF

3. Doutor em Clínica Médica Veterinária, Faculdade de Ciências Agrárias e Veterinárias, UNESP, Jaboticabal, SP

4. Mestranda do Programa de Pós-Graduação em Ciência Animal, União Pioneira de Integração Social, UPIS, Brasília, DF

5. Professor titular, Departamento de Clínica e Cirurgia Veterinária, Faculdade de Ciências Agrárias e Veterinárias, UNESP, Jaboticabal, SP

## ABSTRACT

Corneal sequestrum is an affliction of cats, which is not well defined. The lesion is characterized by degeneration of collagen, followed by accumulation in the cornea of a darkened pigment of variable intensity. Various treatments are adopted taking into account the depth and stage of the lesion, where lamellar keratectomy is the option most often taken. In the present work, four cases are described of Persian breed cats afflicted with corneal se-

questrum, that were submitted to lamellar keratectomy followed by third eyelid flap or conjunctival pedicle flap, and afterward treated topically with the aqueous extract of *Triticum vulgare* (Bandvet®), without adverse effects. The results obtained showed that Bandvet®, despite that it is a pharmaceutical not for ophthalmic use, can be employed in cats after superficial keratectomy.

KEY WORDS: Corneal sequestrum, feline, keratectomy, *Triticum vulgare*

## RESUMO

### UTILIZAÇÃO DO EXTRATO AQUOSO DE *Triticum vulgare* (BANDVET®) APÓS CERATECTOMIA SUPERFICIAL EM SEQÜESTRO CORNEAL FELINO

De causa não bem definida, o seqüestro de córnea é uma afecção que incide sobre os felinos. A lesão caracteriza-se pela degeneração do colágeno, seguida de acúmulo de pigmento enegrecido, de intensidade variável, na córnea. As alternativas terapêuticas são adotadas levando-se em conta a profundidade e o estágio da lesão, sendo a ceratectomia lamelar a opção mais utilizada. No presente trabalho, descrevem-se quatro casos de felinos da raça Persa

acometidos por seqüestro de córnea, que foram submetidos à ceratectomia lamelar seguida de *flap* de terceira pálpebra ou de enxerto pediculado de conjuntiva e, posteriormente, tratados com extrato aquoso de *Triticum vulgare* (Bandvet®), topicamente, sem resultados adversos. Os resultados obtidos mostraram que o Bandvet®, a despeito de não se tratar de fármaco para uso oftálmico, pode ser empregado em felinos após ceratectomia superficial.

PALAVRAS-CHAVES: Ceratectomia, felino, seqüestro corneal, *Triticum vulgare*.

## INTRODUCTION

Corneal sequestrum is an affliction that is relatively common among cats, where the cause is not well defined (PENTLARGE, 1996). Apparently, it is not related to abnormalities of the conjunctiva, nor to qualitative alterations of the lacrimal film (GRAHN et al., 2005). The lesion is characterized by the degeneration of collagen, followed by the accumulation of a darkened pigment of variable intensity. Generally, it is limited to the epithelium and to the middle stroma (STADES, 1999; SLATTER, 2001; KAVINSKY et al., 2004), but can reach Descemet's membrane (PENTLARGE, 1996). This disease affects domestic cats of all ages, with the exception of neonates, and there are no reports of a predilection for sex (GLAZE & GELATT, 1999).

All of the breeds can be affected (GLAZE & GELATT, 1999; SLATTER, 2001; WEICHSLER, 2004); however, Persians and Himalayans are the most often affected (PENTLARGE, 1996; GLAZE & GELATT, 1999), followed by Siamese (ANDREW et al., 2001; SLATTER, 2001; WEICHSLER, 2004), Burmese (PENTLARGE, 1996; GLAZE & GELATT, 1999) and short-haired domestic cats (WEICHSLER, 2004). These breeds display a higher predisposition for the disease because the majority are brachycephalic, whose more pronounced eyeballs are more susceptible to exposure keratitis and other complications (ANDREW et al., 2001).

Corneal sequestrum which was first described more than 50 years ago has been seen frequently. It can manifest also as a result of chronic irritations caused by palpebral defects, or from dry keratoconjunctivitis (GLAZE & GELATT, 1999; STADES et al., 1999). The presence of concomitant diseases supports the hypothesis that corneal sequestrum begins with an irritation of the cornea and with subsequent tissue lesions (GEMENSKY & WILKIE, 2001). These diseases are associated with eventual causative agents of infection by type I feline herpes virus (GLAZE & GELATT, 1999; GEMENSKY & WILKIE, 2001) and, more recently reported, by *Toxoplasma gondii* (CULLEN et al., 2005). The predilection for

certain breeds supports the hypothesis of heredity having a role, where it can be considered as a type of stromal dystrophy (STADES et al., 1999).

The clinical signs of corneal sequestrum are pathognomonic (GLAZE & GELATT, 1999; FEATHERSTONE & SANSOM, 2004). These signs are mummification of the cornea followed by an isolated, darkened lesion, with focal degeneration, which classify this disease as a degenerative corneal affection (STADES et al., 1999). The accumulation of a brown or black pigment of amorphous material, circular or oval in shape, in the central or paracentral region of the cornea, is a result of the degeneration of collagen (PENTLARGE, 1996; SLATTER, 2001). Other designations include black cornea, necrotic keratitis, focal degeneration of the corneal epithelium and corneal mummification (PENTLARGE, 1996; GLAZE & GELATT, 1999; STADES et al., 1999). The disease can manifest in one or both eyes (ANDREW et al., 2001).

The sequestrum is not stained by fluorescein, but areas circumjacent to the lesion can appear poorly stained (GLAZE & GELATT, 1999). With progression, the cornea becomes vascularized and the stroma that surrounds the lesion assumes an edematous appearance. There is discomfort, epiphora and protrusion of the nictitating membrane (STADES et al., 1999).

Histologically, there is the presence of fibroblasts degenerated collagen, surrounded by inflammatory cells. In chronic forms, there is a predominance of macrophages and multinucleated cells (PENTLARGE, 1996). Apoptosis can play an important role in the pathogenesis of corneal sequestrum (CULLEN et al., 2005).

The choice of therapeutic modality depends on the stage of progression of the sequestrum and on its depth in the cornea (PENTLARGE, 1996). Topical antiviral drugs should be used with suspect of herpetic infection (NASISSE, 1998). Superficial keratectomy is recommended for excision of the lesion (MORGAN, 1994; ORIA et al., 2001). Hydrophilic contact lenses, third eyelid flap (PENTLARGE, 1996), tarsorrhaphy, graft and conjunctival pedicle (ANDRADE & LAUS, 1996; GLAZE & GELATT, 1999) or even biological

membranes (LAUS et al., 1999; GALERA et al., 2000) can be employed along with keratectomy.

The prognosis is favorable, notably when appropriate clinical and surgical procedures are employed. The sequestrum can recur, especially when the excision is incomplete (WHITLEY & GILGER, 1999). Corneo-conjunctival coverings or conjunctival pedicles can prevent recurrence of the affection (GLAZE & GELATT, 1999).

Clinical procedures are required. Recently, the efficacy of the aqueous extract of *Triticum vulgare* (Bandvet®) was tested, where it was applied topically on the corneas of dogs, producing satisfactory results (ORTIZ, 2004). In the present study, we determined the efficacy of this product applied topically on the corneas of cats afflicted with sequestrum and that had undergone superficial keratectomy.

## MATERIAL AND METHODS

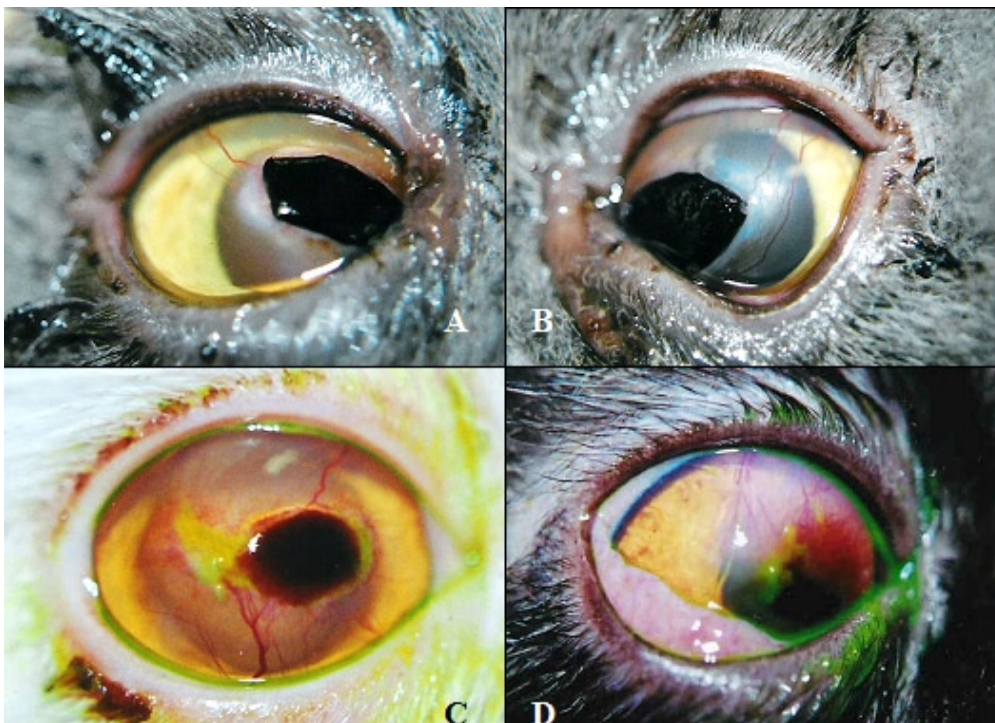### Animals

Four adult Persian cats with ages varying between two and seven years, with two being

males, afflicted with corneal sequestrum with a progression of at least four months, were referred to the Ophthalmology Service of the Veterinary Hospital in the School of Veterinary Medicine, University of Brasilia (UnB) – Brasilia – DF, Brazil.

In one of the animals, the lesion was found to be bilateral (Figures 1A, 1B), whereas in the others it was unilateral (Figures 1C, 1D). Three of the animals had a history of herpetic keratitis which had occurred about a year prior.

The corneal lesions were shown to have a circular or oval appearance, firm consistency and black coloration, and to be centrally localized on the cornea. There was conjunctival hyperemia. In four of the eyes (Figure 1) neofomed vessels were noted circumscribing the lesions to various degrees, and the stroma did not stain with the fluorescein test.<sup>1</sup> In one of the animals, there was granulation tissue on the cornea (Figure 1D) and dense edema circumjacent to the lesion. In this patient, the fluorescein test was positive, notably on the punctiform erosions circumjacent to the main lesion.



**FIGURA 1.** Photographic images of corneal sequestrum in a cat at initial presentation. In A and B, right and left eyes of the same animal. Note, in both, black coloration, raised, diffuse corneal edema, and neovascularization of the cornea. In C, note dense black coloration in central region of the cornea. On the temporal side of the sequestrum, there is edema of the cornea, neofomed vessels and fluorescein staining. In D, note granulation tissue close to the area of sequestrum, and corneal edema in upper and lower nasal quadrant. Note also fluorescein staining.

1. Fluoresceína® – Ophthalmos – São Paulo – SP

## Procedures

### *Pre- and intraoperative*

The animals were submitted to a physical examination and routine laboratory tests for pre-operative evaluation. The tests included a hemogram, biochemical assays, electrocardiogram and culture to isolate corneal pathogens of the lesions.

Keratectomy was carried out with general inhalation anesthesia in semi-closed circuit. Induction was performed with an intravenous bolus injection of propofol,<sup>1</sup> followed by maintenance with isoflurane<sup>2</sup> and oxygen, to maintain a surgical plane of anesthesia. After routine preparation of the operating field, a lamellar keratectomy was performed (Figures 2A, 2B) with a no.15 scalpel<sup>3</sup> using a surgical microscope.<sup>4</sup> A third eyelid flap was performed in four of the eyes, using for

1. Propovan® - Cristália - Itapira - SP.

2. Forane® - ABBOTT - Rio de Janeiro - RJ.

3. d Lâmina de bisturi nº 15 - Wiltex - China.

4. Microscópio Cirúrgico MC - M 900 - D.F. Vasconcelos S.A.- São Paulo - SP

such a pre-set, synthetic nonabsorbable suture 5.0.<sup>5</sup> The other animals underwent keratoplasty with a conjunctival pedicle graft, using standard simple interrupted suturing, utilizing pre-set, synthetic nonabsorbable suture 9-0.<sup>6</sup> Aqueous extract of *Triticum vulgare* (Bandvet®)<sup>7</sup> was applied every 8 h for seven days, from the second week post-operative. At the end of the period, the animals were again submitted to the fluorescein test. In the eye that received the conjunctival pedicle, the section of the pedicle was grafted at 30 days post-operative. the animals were evaluated for up to two years post-operative

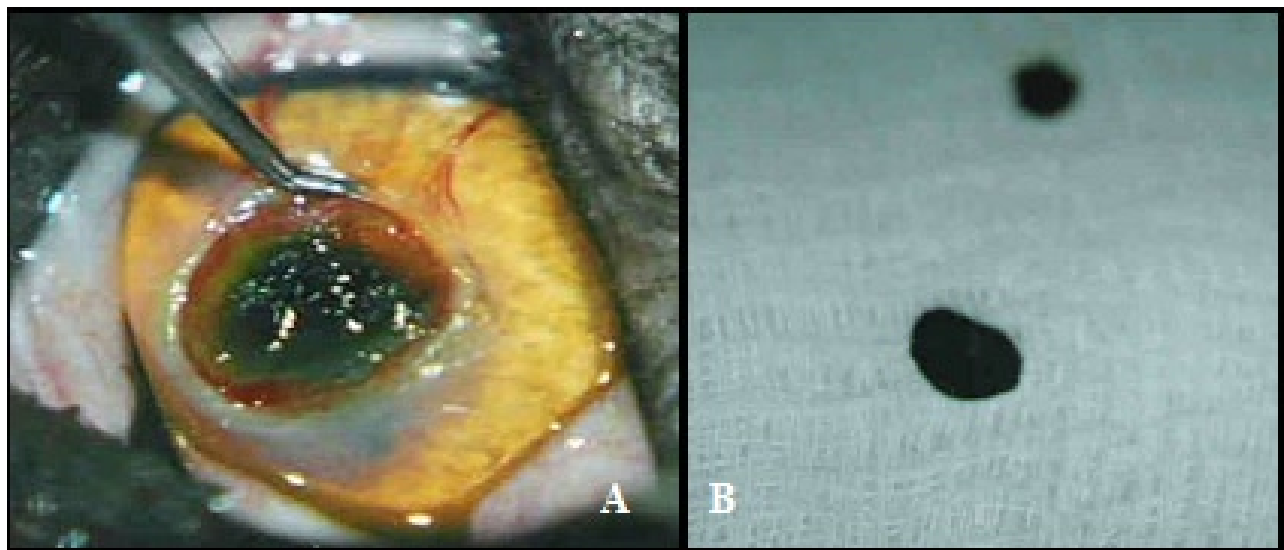
## RESULTS

After removal of the third eyelid flap at seven days post-operative (Figure 3A), diffuse cor-

5. f Fio inabsorvível agulhado nº 5-0 - Johnsons & Johnsons S.A - São José dos Campos - SP.

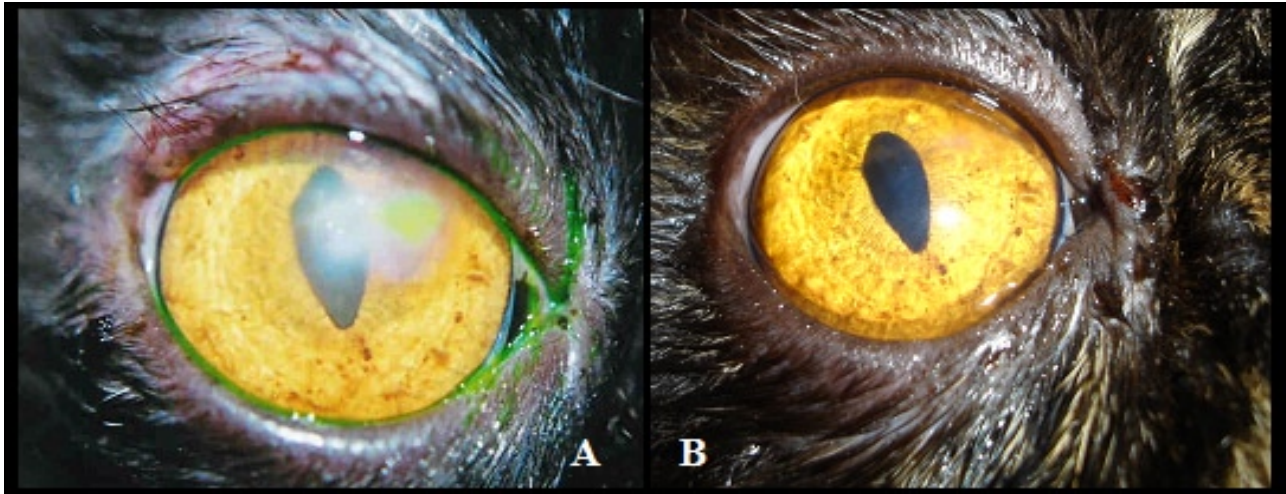
6. g Fio inabsorvível agulhado nº 9-0 - Johnsons & Johnsons S.A. - São José dos Campos - S.P.

7. j Bandvet® - Schering-Plough Coopers. - São Paulo - S.P.



**FIGURE 2.** (A) Photographic image of the eye of a cat with corneal sequestrum, being submitted to superficial keratectomy, and (B) the mummified corneal tissue excised.

### *Post-operative*



**FIGURE 3.** (A) Photographic image of a cat's eye submitted to superficial keratectomy superficial, at seven days post-operative. Note positive fluorescein staining and diffuse edema in the cornea. (B) At twenty days post-operative; note the reduction in edema and negative fluorescein staining

## DISCUSSION

Corneal sequestrum is a disease characterized by collagen degeneration, which manifests as a lesion of brown or black coloration in central or paracentral areas of the cornea, circular or oval in shape, depending the stage of progression (WHITLEY & GILGER, 1999). The clinic appearance is pathognomonic, which favors its diagnosis (STADES et al., 1999; ANDREW et al., 2001).

The uncertain etiology notwithstanding, cats of the Persian breed, such as the ones described in this work, and prior exposure to type I feline herpes virus, as occurred in three of the animals mentioned, can involve predisposing or triggering elements and conditions (STADES et al., 1999).

The type of treatment to be recommended depends on the stage of disease progression and the depth of the lesions (PENTLARGE, 1996; GLAZE & GELATT, 1999). All of the cases reported in the present study involved lesions of chronic progression that were progressive. Corneal degeneration was seen in the superficial stroma in four of five eyes and reached Descemet's membrane in one eye. Keratectomy, although not performed in the early stage, was effective in removing the necrotic tissue and the restoration of visual conditions. Although corneal sequestrum can recur after surgery (GLAZE & GELATT, 1999), such case

was not observed among the animals studied.

It is recommended that the site of keratectomy be protected with a third eyelid flap on superficial lesions or with a 360° corneo-conjunctival pedicle graft in deeper lesions (WHITLEY & GILGER, 1999; ANDREW et al., 2001). A conjunctival pedicle graft was employed in only one case, in which the lesion was deep. In the others, in which the lesion was limited to the superficial stroma, it was decided to protect the cornea with a third eyelid flap, which was then removed at seven days post-operative and not at 14 to 21 days as commonly done (WARD, 1999). This measure made it possible to better examine the effects of Bandvet® on the outcome of the corneal repair.

The aqueous extract of *Triticum vulgare* (Bandvet®) has been shown to be effective in the treatment of tissue lesions (MATERA et al., 2002). It has a mitogenic effect on fibroblasts, as a result of the stimulation of ornithine decarboxylase activity, associated with the activation of EGF and PDGF (MELDOLESI & MAGNI, 1991). The product was evaluated with respect to its effect on the repair of experimental superficial ulcers on the corneas of rabbits, after administering it intra-peritoneally (CAVALIERI et al., 1986), as well as topically on the corneas of dogs, also on experimental lesions after lamellar keratectomy. It was also shown to induce rapid

restructuring of collagen, visualized by light microscopy (ORTIZ, 2004). However, its utilization on the cornea of cats clinically affected had not been previously reported.

### CONCLUSIONS

Based on the results of this study, the aqueous extract of *Triticum vulgare* (Bandvet®) can be utilized on cat corneas after lamellar keratectomy, since no adverse clinical reactions ensued, which leads us to believe that it favors the process of wound repair.

### ACKNOWLEDGEMENTS

Schering-Plough Coopers and Fundação de Empreendimentos Científicos e Tecnológicos (FINATEC).

### REFERENCES

- ANDRADE S. E.; LAUS, J. L. Afecções oftálmicas da córnea. **Clínica Veterinária**, Ano 3, n. 23, p. 12-16, 1996.
- ANDREW, S. E.; TOU, S.; BROOKS, D. E. Corneoconjunctival transposition for the treatment of feline corneal sequestra: a retrospective study of 17 cases (1990-1998). **Veterinary Ophthalmology**, v. 4, n. 2, p. 107-111, 2001.
- CAVALIERE, S.; SPAMPINATO, D.; LAURIA, N.; DRAGO, F. Accelerated recovery of corneal ulcers in rabbits treated with an extract derived from *Triticum vulgare*. **Acta Therapeutica**, v. 12, n. 2, p. 179-184, 1986.
- CULLEN, C.L.; WADOWSKA, D.W.; SINAH, A. et al. Ultrastructural findings in feline corneal sequestra. **Veterinary Ophthalmology**, v. 8, n. 5, p. 295-303, 2005.
- FEATHERSTONE, H. J.; SANSOM, J. Feline Corneal Sequestra: a review of 64 cases (80 eyes) from 1993 to 2000. **Veterinary Ophthalmology**, v. 7, n. 4, p. 213-27, 2004.
- GALERA, P.D.; LAUS, J.L.; FERREIRA, A.F. Use of fresh autogenous vaginal tunic in the experimental lamellar keratoplasty in dogs (*Canis familiaris*, LINNAEUS, 1758). **Brazilian Journal of Veterinary Research Animal Science**, v. 37, n. 6, dez. 2000.
- GEMENSKY, A.J.; WILKIE, D.A. Mineralized corneal sequestrum in a cat. **Journal of American Veterinary Medical Association**, v. 219, n. 11, p. 1568-1572, 2001.
- GLAZE, M.B.; GELATT, K. N. Feline ophthalmology. In: GELATT, K.N. (Ed.). **Veterinary ophthalmology**. 3. ed. Pennsylvania: Lippincott Williams & Wilkins, 1999. p. 997-1052.
- GRAHN, B.H.; SISLER, S.; STOREV, E. Qualitative tear film and conjunctival goblet cell assessment of cats with corneal sequestra. **Veterinary Ophthalmology**, v. 8, n. 3, p. 167-170, 2005.
- KAVINSKI, L.C.; TEIXEIRA, R.B.; PRESOTTO, E.J. Transplante de membrana amniótica para reconstrução da superfície corneal pós ceratectomia em gatos com seqüestro corneal. Disponível em: [www.bducdb.ucdb.br/outros/index.php3?outro=703&curso=171](http://www.bducdb.ucdb.br/outros/index.php3?outro=703&curso=171). Acesso em: 10 jun. 2004.
- LAUS, J. L.; GALERA, P. D.; SCHOKEN-INTURRINO, R. P. et al. Bilateral lamellar keratoplasty in descemetocoele treatment in dog with botulism by use of equine renal capsule and conjunctival pedicle graft. **Ciência Rural**, v. 29, n. 2, p. 355-359, 1999.
- MATERA, J.; FANTONI, D.T.; TATARUNAS, A.C.; ROMAN, M.A.L. Ensaio de avaliação de eficácia e de exequibilidade de uso de creme ou gaze impregnada com *Triticum vulgare* em feridas cutâneas. 1ª. Fase experimental. 2ª. Fase clínica. **Vet News**, v. 2, n. 8, 2002.
- MELDOLESI, J.; MAGNI, M. Lipid metabolites and growth factor action. **Trends in Pharmacological Sciences**, n. 12, p. 362-364, 1991.
- MORGAN, R.V. Feline corneal sequestration: a retrospective study of 42 cases (1987-1991). **Journal of American Animal Hospital Association**, v. 30, p. 24-28, 1994.
- NASSISSE, M.P. **Ocular viral diseases of animals: magrane basic course in ophthalmology**. Madison: University of Wisconsin, 1998.
- ORÍ, A.P.; SOARES, A.M.B.; LAUS, J.L. et al. Feline corneal sequestration. **Ciência Rural**, v. 31, n. 3, p. 553-556, 2001.
- ORTIZ, J.P.D. **Efeitos do Bandvet® sobre a reparação corneal após ceratectomia superficial em cães**. 2004. 68 f. Dissertação (Mestrado em Cirurgia Veterinária) – Faculdade de Ciências Agrárias e Veterinárias, Universidade Estadual Paulista, Jaboticabal, 2004.
- PENTLARGE V. W. Corneal Sequestration in Cats. In: \_\_\_\_\_. **Ophthalmology small animal practice**. New Jersey: Veterinary Learning Systems, 1996. p. 219-225.

SLATTER, D. Cornea and sclera. In: STADES, F. C.; BOEVE, M.H.; NEUMANN, W.; WYMAN, M. **Fundamentals of veterinary ophthalmology**. 3. ed. Philadelphia: Saunders. 2001. p.260-313.

STADES, F. C.; BOEVE, M. H.; NEUMANN, W.; WYMAN, M. **Fundamentos de oftalmologia veterinária**. São Paulo: Manole, 1999. p.110-127.

WARD, D.A. Diseases and Surgery of the Canine Nictitating Membrane. In: GELLATT, K. N. **Veterinary ophthalmology**. 3. ed. Pennsylvania: Lippincott Williams & Wilkins, 1999. p. 609-618.

WEICHSLER N. Seqüestro corneal felino. Disponível em: <http://www.aamefe.org.ar/secuestro.htm>. Acesso em: 9 jun. 2004.

WHITLEY, R.D.; GILGER, B.C. Diseases of the canine cornea and sclera. In: GELATT, K.N. **Veterinary ophthalmology**. 3. ed. Philadelphia: Lea & Febiger. 1999. p. 635-674.

Protocolado em: 15 ago. 2007. Aceito em: 7 abr. 2008.