

CASE REPORT

**ERYTHEMATOUS PAPULAR RASH AFTER
INTERNATIONAL TRAVEL**

Luana Amaral de Moura, Paulo Sergio Emerich Nogueira, Lucia Martins Diniz and Emilyly Neves Souza

ABSTRACT

Bed bugs are hematophagous ectoparasites usually found in bedsteads mattresses, and sheets. The bed bug infestations have been increasing dramatically, but only a few cases have been reported in Brazil. We presented a case of a 49-year-old woman with diffuse, extremely itchy skin lesions, after she returned from an international travel.

KEY WORDS: Cimicidae; bedbugs; prurigo.

INTRODUCTION

Bed bugs are blood-sucking ectoparasites that can be found in bedsteads, mattresses, sheets and cracks in walls (Tammaro et al., 2022). Bed bug infestations have increased dramatically in recent years, and multiple factors seem to be involved, such as insecticide resistance, ineffectiveness of pest control, lack of knowledge about prevention and domestic and international travel expansion (Parola & Izri, 2020).

CASE REPORT

A 49-year-old woman who was born in Espírito Santo, Brazil, presented symptoms of diffuse, extremely itchy skin lesions after she returned from a trip to Orlando, USA. Clinical examination revealed erythematous papules on her face, torso, back and upper and lower limbs (Figure 1).

The patient brought us photographs of insects that were found in her hotel bed, which later were identified as bed bugs (Figure 2) confirming the diagnosis of cimicosis. The patient was treated with antihistamines and a single dose of intramuscular corticosteroid.

Cassiano Antonio Moraes University Hospital, Vitória, ES, Brazil.

Luana Amaral de Moura. ORCID: <https://orcid.org/0000-0002-3697-0186>; Paulo Sergio Emerich Nogueira ORCID: <https://orcid.org/0000-0003-1528-1100>; Lucia Martins Diniz ORCID: <https://orcid.org/0000-0001-8107-8878>; Emilyly Neves Souza ORCID: <https://orcid.org/0000-0003-1151-8537>

Corresponding author: Luana Amaral de Moura. Email: luanamoura@gmail.com

Received for publication: 31/5/2022. Accepted: 6/7/2022.

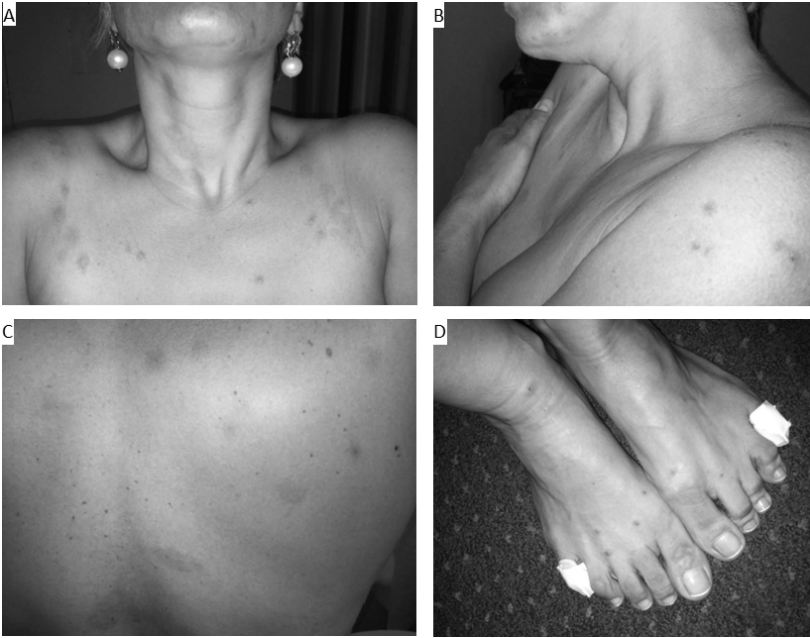

Figure 1. Erythematous, extremely itchy, papules on face, torso (A, B), back (C) and upper and lower limbs (D).



Figure 2. The patient brought us photographs of four insects that she found in her hotel bed, and which were identified as bed bugs.

DISCUSSION

Only five cases of cimicosis were reported in Brazil, although two recent infestations in homeless people's shelter in Belo Horizonte/MG have stimulated research into the susceptibility of parasites to insecticides available in the country (Pessoa et al., 2021). On the other hand, in the United States bed bugs infestations are extremely common, reaching around 80% of hotels according to some data analyses (Parola & Izri, 2020).

The *Cimicidae* family comprises more than one hundred species, but only *Cimex lectularius*, which is more frequent in the tropics, and *Cimex hemipterus*, typical of temperate zones, appear to be anthropophilic (Parola & Izri, 2020; Pessoa et al., 2021). Generally, they are active at night, and feed themselves after biting exposed skin during people's sleep (Tammaro et al., 2022; High, 2017; Eyer-Silva, 2019). Their bites tend to be painless, which is why *Cimicidae* are not often noticed by patients (Bernardes Filho et al., 2015; Criado & Criado, 2011). Despite the previous knowledge about the ability of bed bugs to carry pathogens such as *Trypanosoma cruzi* and *Staphylococcus aureus*, there are still no cases of transmission to humans (Tammaro et al., 2022).

Skin lesions may be noticeable in the morning, after waking up, or they may develop in the following days. Commonly, they are maculopapular, erythematous and pruritic, and located in exposed areas, such as the face, neck, and extremities (Tammaro et al., 2022; Parola & Izri, 2020; Bernardes Filho et al., 2015). In the case reported, some lesions were grouped in a linear distribution, resembling the peculiar pattern "breakfast, lunch and dinner", considered as a characteristic of cimicosis (Figure 3). Although rare, some cases of anaphylaxis and severe urticarial reactions have been reported. (High, 2017; Bernardes Filho et al., 2015).

The diagnosis relies on clinical examination. The cutaneous manifestations are, in general, self-limited, and disappear within seven to 14 days (Tammaro et al., 2022; Parola & Izri, 2020). As there are no guidelines for treatment, managing this is restricted to the professionals' experience. Cleaning the lesions with soap or antiseptics should be instituted. Low-potency topical corticosteroids may be used, as can antihistamines, if there is itching. In cases of secondary infections, the use of oral antibiotic therapy is indicated (Parola & Izri, 2020). Guidance on pest control in the environment and the use of repellents are vital.

In conclusion, we describe a case of cimicosis in a 49-year-old woman who had returned from an international trip. Although there are few cases reported in Brazil, there is a tendency to increase the global incidence of this dermatosis, whose clinical manifestation is similar to other countless skin pathologies. Professionals should be aware of the possibility of cimicosis.

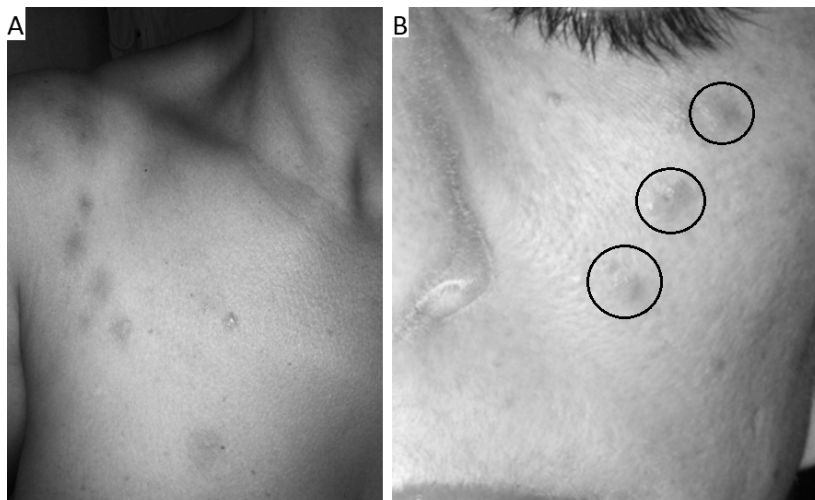


Figure 3. Some lesions were grouped in a linear distribution (A), resembling the peculiar “breakfast, lunch and dinner” pattern (B).

CONFLICT OF INTERESTS

The authors declare that there is no conflict of interest to disclose.

REFERENCES

1. Bernardes Filho F, Quaresma MV, Avelleira JC, Azulay DR, Azulay-Abulafia L, Bastos AQ, Gonçalves TCM. Bed bug dermatitis, description of two cases in Rio de Janeiro, Brazil. *An Bras Dermatol* 90: 240-243, 2015.
2. Criado PR, Criado RF. Bedbugs (Heteroptera, Cimicidae): an etiology of pruritus to be remembered. *An Bras Dermatol* 86: 163-164, 2011.
3. Eyer-Silva WA, Carvalho-Rangel I, Carvalho RS. Bedbugs: Unwelcome Travel Companions. *Rev Soc Bras Med Trop* 52: e20180543, 2019.
4. High WA. Bedbugs: Awareness is key. *Cleve Clin J Med* 84: 212-213, 2017.
5. Parola P, Izri A. Bedbugs. *N Engl J Med* 382: 2230-2237, 2020.
6. Pessoa GCD, Silva DOD, Rosa ACL, Andrade PH, Diotaiuti L. Evaluation of the insecticide susceptibility profile in *Cimex lectularius* (Hemiptera: Cimicidae) in Belo Horizonte (Brazil). *Rev Soc Bras Med Trop* 54: e0707, 2021.
7. Tammaro A, Adebajo GAR, Magri F, Parisella FR, De Marco G. Cutaneous reactions to bedbug bites. *Int J Dermatol* 61: e58-e59, 2022.