
SECONDARY SYPHILIS AND ACUTE PELVIC INFLAMMATORY DISEASE IN PRIMARY HEALTH CARE: A CASE REPORT

Mateus de Paula von Glehn^{1 e 2}, Andrea de Moraes Garay Silva², Leandro Junio Barreto dos Reis¹ and Eleuza Rodrigues Machado¹

ABSTRACT

We present the case of a young woman who was attended to in a family health clinic. The patient had genital lesions and lower abdominal pain, and was diagnosed with syphilis and acute pelvic inflammatory disease. Our aim is to share this experience, which occurred in a basic health unit.

KEY WORDS: Primary health care; syphilis; pelvic inflammatory disease.

RESUMO

Sífilis secundária e doença inflamatória pélvica na atenção primária: relato de caso

Relatamos o caso de uma jovem atendida em equipe de saúde da família. Ela apresentava lesões genitais e dor no baixo ventre, tendo sido estabelecidos os diagnósticos de sífilis e doença inflamatória pélvica aguda. Nosso objetivo é compartilhar a experiência ocorrida em uma unidade de atenção primária à saúde.

DESCRIPTORIOS: Atenção primária à saúde; sífilis; doença inflamatória pélvica.

INTRODUCTION

Syphilis is a chronic systemic disease that is transmitted predominantly through sexual contact. It has a chronic evolution and acute phases, during which temporary cutaneous manifestations occur (1, 2). The diagnosis is established, in most cases, in the latent phase, in which lesions are not present. Due to its transient nature and spontaneous improvement, these lesions may be missed, especially in the

1 Núcleo de Medicina Tropical da Universidade de Brasília, Brazil.

2 Secretaria de Estado de Saúde de Distrito Federal, Brasília, Brazil.

Endereço para correspondência: Quadra 102, Praça Perdiz, lote 04 - Edifício Sol Nascente, apto 903. Águas Claras, 71907-000 Brasília, DF. E-mail: mateusmattaus@yahoo.com.br

Received for publication: 26/12/2014. Reviewed: 13/4/2015. Accepted: 25/5/2015.

female genitals, where the finding of syphilitic lesions is unusual (9, 10). In Brazil, the estimated incidence exceeds 900,000 cases per year (1, 10), it being a reportable disease in the country since 2010 (3, 4). In 2014, 469 cases of acquired syphilis were reported in the Federal District, over 70% of cases being among men (6, 7).

Pelvic inflammatory disease (PID) is caused by micro-organisms of the urogenital tract, with one of the main risk factors being a history of sexually transmitted diseases (STDs), of which *Chlamydia trachomatis* and *Neisseria gonorrhoeae* infections predominate (5,8). The clinical manifestations can vary from subtle to severe symptoms, requiring hospitalization in some cases. Clinical diagnosis of PID is difficult, and a delay in treatment can contribute to inflammatory sequelae in the upper reproductive tract (2). The syndromic management of PID can enhance sensitivity of the diagnosis and avoid a delay in treatment. The Center for Disease Control (CDC) recommends that empirical treatment for PID should be initiated in sexually active young women and other women at risk of STDs if they are experiencing pelvic or lower abdominal pain, in the absence of a putative cause other than PID, associated with one or more of these criteria: cervical motion tenderness; uterine tenderness; adnexal tenderness (5).

This report was approved by the research ethics committee at the Federal District Department of Health (n° 574.816).

CASE REPORT

A 22-year-old, mixed-race, previously healthy woman was attended to in a family health clinic for a complaint of pain in her lower abdomen, which had persisted for a month and was radiating to her back and right upper quadrant. She also complained about foul-smelling vaginal discharge, which had persisted for 1 month. She had been in the same stable relationship for 7 months with a single male partner, with whom she had unprotected sex; both had no history of contracting sexually transmitted diseases. The patient's first sexual intercourse was when she was 18 years old; since then, she had had 3 male partners, including her current partner. Physical examination revealed flat warts on the buttocks, near the intergluteal fold (Figure 1). She had moist, macerated skin with large coalescent ulcers in the intergluteal fold and perianal region associated with a feculent and festering odor (Figure 2).

A purulent secretion was observed in the vaginal introitus, but no lesions were observed on the vulva, vagina, or cervix. A physiological secretion was present in the vagina and cervix. The uterus was tender. The abdomen was flaccid with a large amount of adipose tissue (subject is obese). Bowel sounds were present, with pain on deep palpation of the right hypochondrium and lower abdomen, without guarding or pain upon sudden decompression. The rapid syphilis test detected syphilis, and the rapid anti-HIV test result was negative.

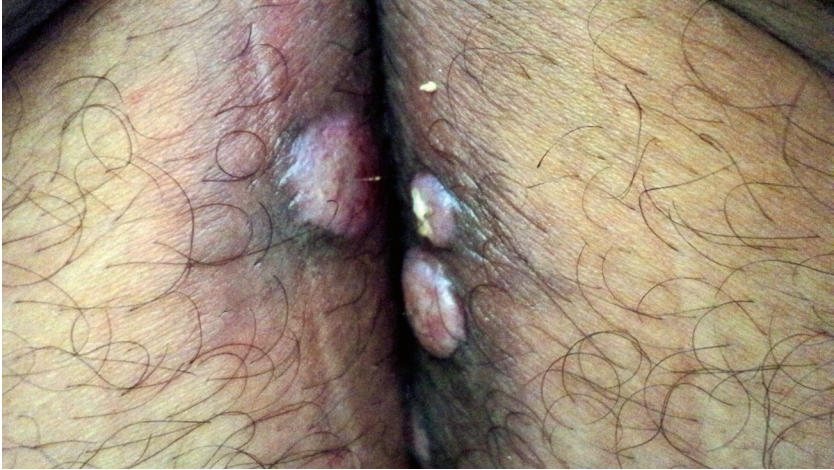

Figure 1. Flat warts near the intergluteal fold

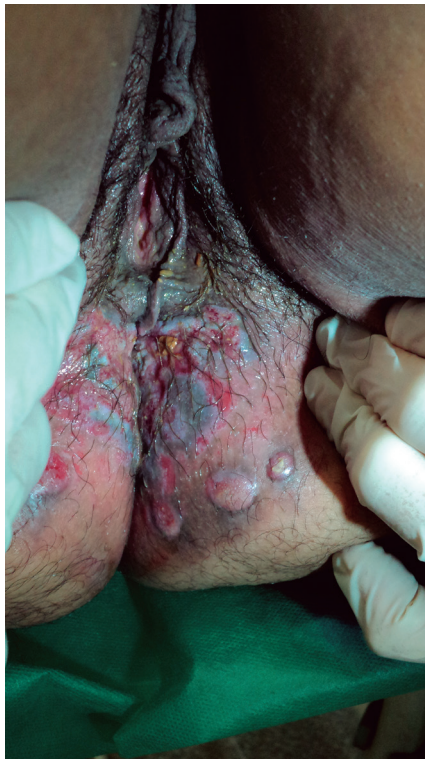

Figure 2. Genital ulcers in the perineal region

Cervical samples were obtained for oncotoc cytology (Papanicolaou test) along with blood samples for VDRL tests. The results indicated treatment of syphilis with 7,200,000 IU of benzathine penicillin and treatment of acute pelvic inflammatory disease (PID); single-dose intramuscular 250 mg ceftriaxone + 400 mg metronidazole twice a day for 14 days + 100 mg doxycycline twice a day for 14 days, in accordance with guidelines proposed by the Brazilian Ministry of Health and CDC (2, 5). The patient was requested to return in 5 days, with instructions to seek emergency care if conditions worsened, as the clinic was not open during weekends.

On returning, she reported complete improvement in symptoms and complete healing of ulcers, with partial reduction of the flat warts (Figure 3). One side effect reported was a slight decrease in stool consistency. The VDRL ratio was 1:128. When the patient returned 1 week later, her lesions had completely healed.

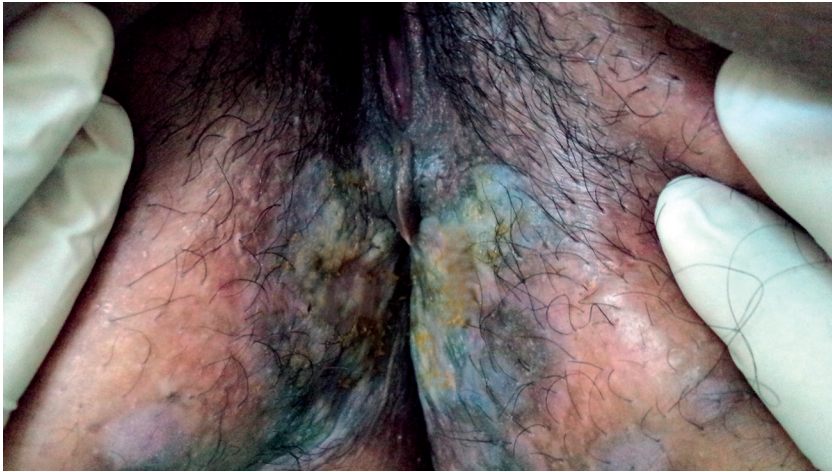


Figure 3. Healing of lesions 6 days after the first dose of benzathine penicillin

A cytological study revealed a Low-Grade Squamous Intraepithelial Lesion (LSIL). A new VDRL test was performed 3 months later, obtaining a result of 1:16. Her partner, who showed no lesions and also denied previous lesions, had a VDRL ratio of 1:128 and a positive result in the syphilis rapid test. He was diagnosed with latent syphilis of an unknown duration and was treated with benzathine penicillin 7,200,000 IU, along with presumptive treatment for Chlamydia and Gonococcus.

DISCUSSION

This study is concerned with a young nulligravida woman, who had sought medical attention on two previous occasions due to discharge and pelvic

pain. The discharge was in fact a purulent secretion originating from perigenital lesions, which the patient had not noticed. The patient probably failed to notice the lesions not only because she was obese but also because she did not perform self-assessments. Therefore, a genital examination is vital during the consultatory visit. It is important to remember that PID may compromise the reproductive future of a couple and delayed treatment is associated with greater risk. The lesions that occurred are characteristic of secondary syphilis; however, as it was not possible to determine when contamination occurred, a treatment of 3 doses of 2.4 million IU of benzathine penicillin was given.

We did not perform laboratory tests, such as erythrocyte sedimentation rate or C-reactive protein, because our unit did not have the necessary laboratory facilities. In order not to lose the opportunity to initiate treatment, we dispensed on the basis of the tests available at the time. However, the availability of rapid tests for HIV and syphilis can be considered a positive feature.

We conclude that the professional should consider syphilis as a disease that is still important in our reality and that sexually transmitted infections may occur simultaneously, as well as an increase in the risk of transmitting and acquiring HIV. Health professionals must be made aware of the importance of timely diagnosis, and the appropriate management and health education of individuals and the community.

ACKNOWLEDGMENTS

The authors thank the patient for her collaboration.

CONFLICTS OF INTERESTS

no conflicts of interest to declare.

REFERENCES

1. Brasil. Ministério da Saúde. Secretaria de Vigilância em Saúde. Departamento de Vigilância Epidemiológica. *Doenças infecciosas e parasitárias: guia de bolso*. 8ª ed. Brasília, 2010. pg 363-376.
2. Centers for Disease Control and Prevention. *Sexually Transmitted Diseases Treatment Guidelines*. MMWR 2010; 59(No.RR-12):63-67. Available at: <http://www.cdc.gov/mmwr/pdf/tr/tr5912.pdf>.
3. Governo do Distrito Federal. Secretaria de Estado de Saúde. Subsecretaria de Vigilância à saúde. Gerência de DST e Aids. *Informativo epidemiológico de sífilis, hepatites B e C e Aids no Distrito Federal*, ano 1, nº 1. 2014.
4. *Informativo epidemiológico de sífilis, hepatites B e C e Aids no Distrito Federal*, ano 1, nº 2. 2014.
5. Lima YAR, Turchi MD, Fonseca ZC, Garcia FLB, Cardoso FAB, Reis MNG, Guimarães EMB, Alves RRF, Carvalho NR, Alves MFC. Sexually transmitted bacterial infections among young women in Central Western Brazil. *Int J Infect Dis* 25: 16-21, 2014.
6. Ministério da Saúde. Portaria nº 104, de 25 de janeiro de 2011. Available at: http://bvsmms.saude.gov.br/bvs/saudelegis/gm/2011/prt0104_25_01_2011.html.
7. Ministério da Saúde. Portaria nº 2.472, de 31 de agosto de 2010. Available at: http://bvsmms.saude.gov.br/bvs/saudelegis/gm/2010/prt2472_31_08_2010.html.

8. Passos MRL, Nahn Junior EP. Sífilis. In: Tavares W, Marinho LAC. *Rotinas de Diagnóstico e Tratamento das Doenças Infecciosas e Parasitárias*. 2. ed. São Paulo: Atheneu, 2007. Cap. 144. p. 913-925.
9. Passos MRL, Giraldo PC. *Deesetologia no Bolso: o que deve saber um profissional que atende DST*. 5ª ed. Rio de Janeiro: Revinter. 2011.
10. Secretaria de Vigilância em Saúde. *Programa Nacional de DST e Aids. Manual de Bolso das Doenças Sexualmente Transmissíveis/Ministério da Saúde, Secretaria de Vigilância em Saúde, Programa Nacional de DST e Aids*. Brasília: Ministério da Saúde. 2005.