







REVIEW ARTICLE

Clinical manifestations presented by children infected with COVID-19: an integrative review

Manifestações clínicas apresentadas por crianças infectadas pela COVID-19: revisão integrativa

Jallyne Colares Bezerra¹ , Hévila Ferreira Gomes Medeiros Braga¹ , Francisca Mayra de Sousa Melo² , Aline Pereira do Nascimento¹ , Flavio Brayan Balbino Silva¹ , Emanuella Silva Joventino Melo¹ 

ABSTRACT

Objective: The objective was to analyze the scientific evidence on the clinical manifestations presented by children infected with COVID-19. **Method:** Integrative review conducted in PubMed, CINAHL, LILACS, Web of Science, SCOPUS and SCIENCE DIRECT databases from December 2019 to June 2020. Twenty articles were selected. **Results:** Two thematic categories emerged: “Mild or moderate clinical features” and “COVID-19 associated multisystem inflammatory syndrome”. Most children were infected by their parents or close relatives. The symptoms presented by children were predominantly mild or moderate and with quick recovery. The main clinical manifestations presented by children infected with SARS-CoV-2 were fever, gastrointestinal signs, respiratory signs, and more recently, symptoms similar to those of Kawasaki Disease, which was called COVID-19 associated multisystem inflammatory syndrome. **Conclusion:** Faced with this, health professionals must be alert to recognize these cases in order to offer appropriate and timely management during health care.

Descriptors: Coronavirus Infections; COVID-19; Signs and Symptoms; Child Health; Nursing.

RESUMO

Objetivo: Analisar as evidências científicas sobre as manifestações clínicas apresentadas por crianças infectadas pela COVID-19. **Método:** Revisão integrativa conduzida nas bases de dados PubMed, CINAHL, LILACS, Web of Science, SCOPUS E SCIENCE DIRECT. Foram selecionados 20 artigos. **Resultados:** Emergiram duas categorias temáticas: “Características clínicas leves ou moderadas” e “Síndrome inflamatória multissistêmica associada à COVID-19”. A maioria das crianças foi infectada pelos pais ou parentes próximos. A sintomatologia apresentada pelo público infantil foi predominantemente leve ou moderada e de recuperação rápida. As principais manifestações clínicas apresentadas pelas crianças infectadas pelo SARS-CoV-2 foram febre, sinais gastrointestinais, sinais respiratórios, e mais recente, sintomas semelhantes a Doença de Kawasaki, sendo denominada como síndrome inflamatória multissistêmica associada à COVID-19. **Conclusão:** Frente a isso, os profissionais da saúde devem estar alertas para o reconhecimento desses casos para possibilitar o manejo adequado e oportuno durante a assistência à saúde.

Descritores: Infecções por Coronavirus; COVID-19; Sinais e Sintomas; Saúde da Criança; Enfermagem.

¹Universidade da Integração Internacional da Lusofonia Afro-Brasileira – Redenção (CE), Brasil. E-mails: jallynecolares@gmail.com, hevila.medeiros.hm@gmail.com, aline.nascimento86@hotmail.com, brayanbalbino@gmail.com, ejoventino@unilab.edu.br

²Faculdade Princesa do Oeste – Crateús (CE), Brasil. E-mail: mayrasmelo18@gmail.com

How to cite this article: Bezerra JC, Braga HFGM, Melo FMS, Nascimento AP, Silva FBB, Melo ESJ. Clinical manifestations presented by children infected with COVID-19: an integrative review. Rev. Eletr. Enferm. [Internet]. 2021 [cited _____];23:65966. Available from: <https://doi.org/10.5216/ree.v23.65966>.

Received on: 10/01/2020. Accepted on: 04/07/2021. Available on: 07/13/2021.

INTRODUCTION

In December 2019, an outbreak of pneumonia of unknown etiology related to a seafood market emerged in Wuhan city, Hubei province, China. Later, it was discovered that the virus, called SARS-CoV-2, belongs to the *Coronaviridae* family and is the agent responsible for COVID-19, the severe acute respiratory syndrome (SARS)⁽¹⁾.

In view of this, on January 30, 2020, the World Health Organization (WHO) declared that the SARS-CoV-2 outbreak constituted a public health emergency of international concern; on March 11, 2020, the WHO characterized COVID-19 as a pandemic⁽²⁾ and in September 2020, it became known as a syndemic, since the social aspect of some vulnerable groups is the key element aggregating the interaction of diseases⁽³⁾.

In a short time, the virus spread to other cities in China and later to the world. Until November 17, 2020, COVID-19 was responsible for more than 54,771,888 confirmed cases worldwide and 1,324,249 deaths⁽⁴⁾. In Brazil, 5,911,758 cases and 166,699 deaths were reported until that same date⁽⁵⁾.

The number of COVID-19 cases registered in children is relatively small compared to the total number in the general population. In February 2020, 2.4% of the 75,465 cases (confirmed and suspected) in China occurred in children, 1.2% in Italy and 5% in the United States of America⁽⁶⁾. In Brazil, less than 1% of children between one and five years of age were hospitalized with symptoms of the disease⁽⁵⁾.

It is noteworthy that clinically differentiating the symptoms caused by SARS-CoV-2 from those caused by other viral etiologies is still difficult, which may result in underreporting of data from the pediatric population, since most infected children and adolescents are asymptomatic or oligosymptomatic, with mild symptoms involving only the upper airways⁽⁷⁾.

Thus, most symptoms detected in pediatric cases are fever, cough, difficulty breathing, sore throat, nasal congestion, headache, malaise and myalgia⁽⁷⁾. However, more serious cases also exist, as cited at the end of April 2020 by the UK Pediatric Society, reporting the identification of a new clinical presentation in children and adolescents, possibly associated with COVID-19. The patients presented a multisystem inflammatory syndrome with clinical manifestations and alterations in complementary exams similar to those observed in children with Kawasaki syndrome, incomplete Kawasaki and/or toxic shock syndrome, thus pointing to a new facet of this disease^(8,9).

As the new coronavirus is not the only microorganism circulating during the pandemic, children often present respiratory infections with symptoms similar to those of COVID-19 during a seasonal period. Therefore, the need to know the difference between infections in order to perform an appropriate diagnosis and an assertive care plan.

In addition, in view of the variability in the range of clinical manifestations of this new disease, nurses need to recognize the signs and symptoms of COVID-19 early in order to guide the patient and family members about the recommended behaviors, develop a care plan aimed at each case and intervene to prevent the worsening of the child's health status. Nursing has a fundamental role in promoting the child's wellbeing through qualified care and minimization of the signs and symptoms caused by the new coronavirus.

In view of the constant discoveries related to the clinical presentations of COVID-19, we sought to synthesize the theme using the following guiding question: What are the clinical manifestations presented by children infected with COVID-19?

Because this is a new disease and due to the diversity of symptoms that vary according to each patient, it is urgent to investigate in the literature the clinical characteristics of COVID-19 in children, which will make this knowledge feasible for healthcare professionals, especially for nurses, since they are often the first to have contact with the patient. Therefore, the objective of this study is to analyze the scientific evidence on clinical manifestations presented by children infected with COVID-19.

METHOD

This is an integrative literature review consisting of the following steps: development of the guiding question, establishment of inclusion and exclusion criteria of articles, definition of the information to be extracted from studies, selection of articles in the literature, critical analysis of included studies, discussion of results and presentation of the review/synthesis of knowledge⁽¹⁰⁾. Aiming at a greater rigor in the critical analysis of the selected studies, the recommendations of the Preferred Reporting Items for Systematic Reviews and Meta-Analyses (PRISMA) checklist were followed⁽¹¹⁾.

After defining the theme addressed in the study, the following guiding question was prepared to guide the search for scientific productions: What are the clinical manifestations presented by children infected with COVID-19?

Subsequently, the search for scientific articles on the theme was performed in June 2020. The bibliographic survey was conducted in the following databases: National Library of Medicine National Institutes of Health (PubMed), Cumulative Index of Nursing and Allied Health Literature (CINAHL), Latin American and Caribbean Health Sciences Literature (LILACS), Web of Science, SCOPUS and SCIENCE DIRECT.

For the search strategy, the following Health Sciences Descriptors (DeCS) were used: "coronavirus COVID-19", "novel coronavirus", "SARS-CoV-2", "2019-nCoV",

“coronavirus disease 2019” and “COVID-19”. The crossings were associated using the Boolean operator “OR”.

The inclusion criteria adopted were productions in full, available for free, addressing the clinical characteristics of children infected with COVID-19 and published in the period from December 2019 to June 2020, the period of onset and spread of the disease. In addition, the following were excluded from the study: editorials, letters to the editor, annals of events, monographs, theses, dissertations, reports, as well as duplicated productions that did not answer the guiding question.

After the search and identification of scientific productions, the title and abstract of these works were read in order to analyze if they answered the guiding question of this study. The articles included after this initial reading were read in full and an exploratory reading was performed to ensure they met the requirements of the study.

After collection, the articles were organized according to the database, title, journal, year of publication, area of publication, type of publication, abstract, objective of the study, type of method, main results and outcome.

Figure 1 represents the flowchart based on PRISMA containing the steps for identification and selection of articles. Initially, 58,617 productions were found in the selected databases, of which 6,630 met the inclusion criteria. The title and abstract of the 6,630 pre-selected articles were read, 6,255 were excluded for not answering the guiding question and 300 for being duplicated. Thus, 75 articles were read in full, 49 were excluded for not answering the guiding question and six for being editorials, totaling 55 excluded manuscripts. Therefore, 20 articles were included in the corpus of this review.

RESULTS

Twenty articles were part of this review, which are described in Chart 1. Most studies were published in PubMed (n=15), in English (n=18) and all of them in medical journals (n=20). Regarding the years of publication, all studies were published in 2020 (n=20). As for the content of articles, we highlight the convergence of knowledge produced to the categories: “Mild or moderate

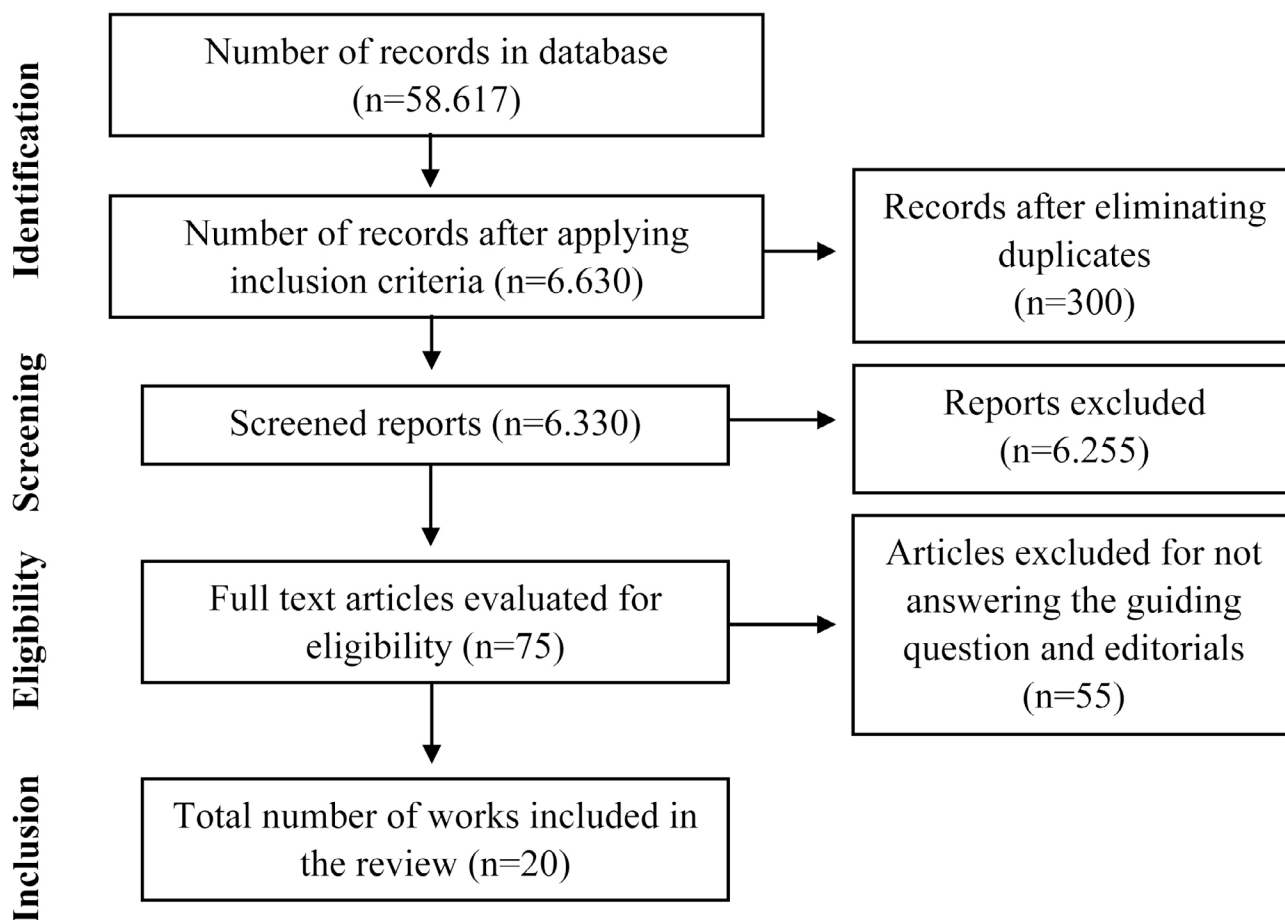


Figure 1. Flowchart of the steps of identification and selection of productions on the clinical characteristics presented by children infected with COVID-19. Brazil, 2020.

Chart 1. Description of articles selected according to the title of manuscript, year, journal, type of study, objective, sample, age group, outcome and category. Brazil, 2020.

Manuscript title	Year, Journal, Type of study	Objective	Sample, Age group	Outcome	Category
Clinical features of pediatric patients with COVID-19: a report of two family cluster cases.	2020, World Journal of Pediatrics, Retrospective study.	To help pediatricians with the early recognition of cases of children infected with COVID-19.	02 patients aged nine to 15 years.	The two children confirmed had only mild respiratory or gastrointestinal symptoms. Both had normal chest CT images.	Mild or moderate clinical features.
Clinical features of severe pediatric patients with coronavirus disease 2019 in Wuhan: a single center's observational study.	2020, World Journal of Pediatrics, Exploratory study.	To describe the clinical features of critically ill pediatric patients with COVID-19.	08 patients aged 0 to 15 years.	Polypnea was the most common symptom, followed by fever and cough. Common image changes included various patch-like shadows and ground-glass opacity.	Mild or moderate clinical features.
First pediatric case of coronavirus disease 2019 in Korea.	2020, Journal of Korean Medicine Science, Case study.	To report the first pediatric case of Covid-19 in Korea.	01 patient, 10 years old.	The only symptoms of the child were low-grade fever and a small amount of sputum. Chest CT showed mild pneumonia.	Mild or moderate clinical features.
Characteristics of pediatric SARS-CoV-2 infection and potential evidence for persistent fecal viral shedding.	2020, Nature Medicine, Epidemiological study.	To report the epidemiological and clinical characteristics of ten children infected with SARS-CoV-2.	10 patients aged between two months and 15 years.	The ten pediatric patients had mild symptoms. None of the patients showed clear clinical signs or chest radiological findings consistent with pneumonia.	Mild or moderate clinical features.
Chest computed tomography in children with COVID-19 respiratory infection.	2020, Pediatric Radiology, Exploratory study.	To describe chest CT findings in children with COVID-19.	05 patients aged between ten months and six years.	Three children had abnormalities on the first CT scan in the form of irregular ground-glass opacities.	Mild or moderate clinical features.
SARS-CoV-2 infection in children: transmission dynamics and clinical characteristics.	2020, Journal of the Formosan Medical Association, Epidemiological study.	To characterize the transmission dynamics and clinical characteristics of children infected with Covid-19.	01 patient, three months old.	The patient had fever for one day and a chest CT with slightly increased infiltration in the lungs.	Mild or moderate clinical features.
Insight into COVID-2019 for pediatricians.	2020, Pediatric Pulmonology, Case study.	To discuss the clinical features, prevention and control measures,	02 patients, both four years old.	The conditions of the two cases were relatively mild, without fever or pneumonia	Mild or moderate clinical features.

Continue...

Quadro 1. Continuation.

Manuscript title	Year, Journal, Type of study	Objective	Sample, Age group	Outcome	Category
	2020, Pediatric Pulmonology, Case study.	outcomes, diagnosis and treatment of pediatric cases.		and had a good prognosis.	
Clinical and epidemiological features of 36 children with coronavirus disease 2019 (COVID-19) in Zhejiang, China: an observational cohort study.	2020, Lancet Infectious Diseases, Retrospective study.	To describe the epidemiological and clinical aspects of pediatric patients and provide information for the prevention and treatment of COVID-19 in children.	36 patients aged 0 to 16 years.	Although fever, dry cough and mild pneumonia are common manifestations, almost half of the patients do not have symptoms and radiological findings that are not normal.	Mild or moderate clinical features.
SARS-CoV-2 infection with gastrointestinal symptoms as the first manifestation in a neonate.	2020, Chinese Journal Contemporary Pediatrics, Case study.	To report cases to improve understanding of SARS-CoV-2 infection in neonates.	01 patient aged 0 years.	Symptoms in neonatal cases may not be typical. Gastrointestinal symptoms such as vomiting and diarrhea can also be used as the first manifestation of SARS-CoV-2 infection.	Mild or moderate clinical features.
Twin girls infected with SARS-CoV-2.	2020, Chinese Journal of Contemporary Pediatrics, Case study.	To report the diagnosis and treatment of twin girls diagnosed with acute severe respiratory infection by coronavirus.	02 patients, both one year old.	Both girls had mild symptoms and rapid recovery, suggesting that SARS-CoV-2 infection in children may be mild and have a good prognosis.	Mild or moderate clinical features.
Images in practice: painful cutaneous vasculitis in a SARS-CoV-2 IgG-positive child.	2020, Pain Therapy, Case study.	To observe pediatric patients who tested positive IgG for SARS-CoV-2 with skin lesions on the feet.	01 patient aged 11 years.	The patient had erythematous chilblain-like skin lesions on her feet and several ulcerative lesions with dyschromia of the nails.	Mild or moderate clinical features.
Pediatric coronavirus disease 2019 (COVID-19): an insight from west of Iran.	2020, Northern Clinics of Istanbul, Descriptive study.	To study the clinical, laboratory and radiological characteristics of pediatric patients infected with SARS-CoV-2.	30 patients, aged between 0 and 15 years.	The most common symptoms were fever, cough and dyspnea, and the most common sign was tachypnea. Nineteen out of the 30 patients had ground-glass opacities on CT.	Mild or moderate clinical features.

Continue...

Quadro 1. Continuation.

Manuscript title	Year, Journal, Type of study	Objective	Sample, Age group	Outcome	Category
Cardiac MRI in Children with Multisystem Inflammatory Syndrome with COVID-19.	2020, Radiology, Retrospective study.	To point out the cardiac findings in four children and adolescents with similar characteristics to multisystem inflammatory syndrome in children and to Kawasaki disease associated with COVID-19.	08 patients aged between 0 and six years.	The findings favor post-infectious myocarditis in children and adolescents with COVID-19.	Multisystem inflammatory syndrome.
Features of COVID-19 post-infectious cytokine release syndrome in children presenting to the emergency department.	2020, American Journal of Emergency Medicine, Case study.	To describe the characteristics of the post-infectious cytokine release syndrome associated with COVID-19 in children.	04 patients aged between five and 13 years.	Patients who present with post-infectious cytokine associated with COVID-19 appear to have prolonged fever (five days or more) and gastrointestinal symptoms with or without rash.	Multisystem inflammatory syndrome.
Kawasaki disease features and myocarditis in a patient with COVID-19.	2020, Pediatric Cardiology, Case study.	To describe the characteristics of Kawasaki disease and myocarditis in a patient with COVID-19.	01 patient, aged ten years.	The child had fever for seven days, fatigue, diarrhea, cough, rash and conjunctivitis. Cardiac examination revealed tachycardia with no murmur auscultated.	Multisystem inflammatory syndrome.
Paediatric Inflammatory Multisystem Syndrome: Temporally Associated with SARS-CoV-2 (PIMS-TS): cardiac features, management and short-term outcomes at a UK tertiary paediatric hospital.	2020, Pediatric Cardiology, Retrospective study.	To describe cardiac manifestations, management and initial results for children admitted to Children's Hospital in Birmingham.	15 patients aged six to 11 years.	All patients were discharged alive. The entire cohort with multisystem syndrome temporally associated with SARS-CoV-2 had cardiac problems.	Multisystem inflammatory syndrome.
An outbreak of severe Kawasaki-like disease at the Italian epicentre of the SARS-CoV-2 epidemic: an observational cohort study.	2020, Lancet, Retrospective study.	To assess the incidence and characteristics of patients with Kawasaki-like disease diagnosed during the SARS-CoV-2 epidemic.	30 patients aged 0 to 7 years.	Five patients were diagnosed with incomplete Kawasaki disease, two patients had bulbar non-exudative conjunctivitis; and polymorphic rash. One patient had only	Multisystem inflammatory syndrome.

Continue...

Quadro 1. Continuation.

Manuscript title	Year, Journal, Type of study	Objective	Sample, Age group	Outcome	Category
				bulbar non-exudative conjunctivitis and a polymorphic rash.	
Toxic shock-like syndrome and COVID-19: multisystem inflammatory syndrome in children (MIS-C).	2020, American Journal of Emergency Medicine, Case study.	To describe a case of multisystem inflammatory syndrome in a child.	01 patient aged 11 years.	Although the case described has more consistent features with a toxic shock syndrome, incomplete Kawasaki disease cannot be excluded by the general clinical picture.	Multisystem inflammatory syndrome.
Multisystem Inflammatory Syndrome in Children Associated with Severe Acute Respiratory Syndrome Coronavirus 2 Infection (MIS-C): A Multi-institutional Study from New York City.	2020, The Journal of Pediatrics, Retrospective observational study.	To evaluate clinical features and outcomes of SARS-CoV-2 associated with multisystem inflammatory syndrome in children.	15 patients aged 0 to 13 years.	Critically ill children with COVID-19-associated multisystem inflammatory syndrome have a broader spectrum of severity.	Multisystem inflammatory syndrome.
Novel paediatric presentation of COVID-19 with ARDS and cytokine storm syndrome without respiratory symptoms.	2020, Lancet Rheumatology, Case study.	To report the case of a 14-year-old teenager with cytokine storm syndrome and ARDS.	01 patient aged 14 years.	Patient presented fever, abdominal pain, nausea and vomiting, but no respiratory symptoms. Within 24 hours of admission, the patient developed dyspnea, cough, and need for oxygen.	Multisystem inflammatory syndrome.

clinical features” and “COVID-19 associated multisystem inflammatory syndrome”.

For a better understanding, Chart 1 presents the information of the selected articles regarding the title of manuscript, year, journal, type of study, objective, sample, age, outcome and category.

Among the studies comprising this review, some included patients over the age of 16 as young children. Note that subjects under 16 were considered as children, according to the sole paragraph of the National Policy for Comprehensive Child Health Care. This addresses that for the purposes of pediatric care in the Brazilian SUS, the National Policy for Comprehensive Child Health Care will include children and adolescents up to the age of 15 years, that is, from zero until turning 16 or 192 months⁽¹²⁾.

Thus, the articles were analyzed, and the number of patients who fell into the age range mentioned above was listed.

DISCUSSION

Currently, information of children infected with COVID-19 demonstrates the lack of a clear consensus on the clinical characteristics manifested by this group, as this population mostly presents the mild form of the disease, which is similar to that of a common flu⁽⁶⁾. However, in recent months, severe forms of illness that differ from flu-like symptoms have been correlated with COVID-19. The categories presented below involve “Mild or moderate clinical features presented by children infected with COVID-19” and “COVID-19 associated multisystem inflammatory syndrome”.

Category 1: Mild or moderate clinical features presented by children infected with COVID-19

The literature reports that at the beginning of the pandemic, contamination of the pediatric population occurred mainly through contact with adults who had previously traveled to cities considered to be the epicenter of the pandemic, such as Hubei province, China^(1,13,14). A study conducted in China showed that five out of eight children were infected due to close contacts with family members confirmed with COVID-19 who had traveled for work or pleasure to that city⁽¹⁵⁾. However, in a short time, the status of community transmission of the coronavirus was decreed, that is, when it is impossible to trace the first patient that originated the chains of infection.

The clinical picture of the disease can be considered mild, moderate, severe or critical. Thus, the disease can manifest from the involvement of upper airways in mild cases, pneumonia without complications and hypoxemia in moderate cases, severe pneumonia with respiratory distress in severe cases, and severe acute respiratory syndrome (SARS) with involvement of several organs representing risk of death in critical cases⁽¹⁶⁾.

A study on clinical manifestations of COVID-19 in children found that of the 1,124 cases of the studies included, the most prevalent symptom was fever, followed by cough and nasal symptoms (runny nose and nasal congestion). Furthermore, about half of children were asymptomatic or had mild cases⁽¹⁷⁾.

In short, the most prevalent symptoms presented by children were mild such as fever, cough, runny nose, headache, nausea, vomiting and diarrhea^(1,2,13-18). It is noteworthy that the lower airway is the main target of SARS-CoV-2, although the studies available so far show this involvement seems to be uncommon in children^(14,19).

This may be a result of the greater innate immunity to respiratory tract infection in children than in adults, as in this population, the adaptive immune response is superior and the protein that binds to the angiotensin-converting enzyme is less mature in younger people, what makes such a connection difficult. Thus, children's ability to trigger an acute inflammatory response to SARS-CoV-2 is weak, which may also contribute to a better outcome. However, such particularities do not eliminate the possibility of serious cases and even death, especially in children with comorbidities^(6,20).

Given the clinical spectrum of the disease caused by the new coronavirus in children, it is necessary to be aware of fever, a frequent symptomatology that is usually high and prolonged. Thus, the recognition of this symptom helps in the timely and appropriate management during the care of children with suspicion or confirmation of COVID-19⁽¹⁶⁾.

Among the most common manifestations observed, in addition to fever, gastrointestinal symptoms have been frequently presented by children infected with COVID-19^(1,13,18,21,22) and the concern about possible fecal-oral transmission has increased considerably⁽¹³⁾. A study of ten children who tested positive for COVID-19 showed that eight children tested positive on rectal swabs, even after the nasopharyngeal test was negative, suggesting that the gastrointestinal tract may release the virus and fecal-oral transmission may be possible⁽¹³⁾.

This finding suggests that the rectal swab test may be more useful than the nasopharyngeal swab test to judge the effectiveness of treatment and determine when the quarantine ends, since the virus remains in the digestive system longer than in the respiratory tract^(5,13,23).

Dermatological diseases stand out among those being associated with COVID-19 and several studies point to the development of skin rashes in the pediatric population^(20,24-26). Among them, in a study, a ten-year-old child with erythematous, chilblain-like lesions on the feet associated with SARS-CoV-2 was identified. In the previous six weeks, the child did not present fever, cough, malaise or asthenia, complained of pain and mild to moderate itching that was treated with dermatological ointment and paracetamol⁽²⁴⁾.

Given the diversity of clinical manifestations, another factor that has concerned researchers is intrauterine vertical transmission (mother-fetus), as there is no scientific evidence demonstrating its existence. The COVID-19 virus was not detected in breast milk either. Therefore, the main concern is that an infected mother can transmit the virus through respiratory droplets at the time of breastfeeding⁽⁶⁾.

A study conducted with a newborn showed that the first symptoms presented by the child infected with COVID-19 was refusal of breast milk on the 17th day after birth. At the same time, the number of bowel movements increased to four to five times a day and stool was relatively thin, with an average body temperature of 37.7°C. The child's mother manifested symptoms of the disease one day before delivery and tested positive along with the father⁽¹⁸⁾.

Importantly, breastfeeding during maternal COVID-19 infection is not contraindicated by the Centers for Disease Control and Prevention and the Royal College of Obstetricians and Gynaecologists, but precautions must be taken to prevent the virus from spreading to the newborn, including hand washing before touching the baby and wearing a face mask. In the case of breast milk extraction, recommendations for cleaning the pumps after each use must be strictly observed⁽²⁷⁾.

Category 2: COVID-19 associated multisystem inflammatory syndrome

Respiratory manifestations are mild most of the time, although severe manifestations of the disease have

been reported in recent months, as children had similar symptoms to those of the Kawasaki Disease (KD), and this new manifestation was classified by the Centers for Disease Control and Prevention (CDC) as “COVID-19 associated multisystem inflammatory syndrome”^(2,9,20-25,28).

Furthermore, common respiratory viruses may be responsible for Kawasaki disease, especially enteroviruses, adenoviruses, rhinoviruses and coronaviruses⁽²⁹⁾.

Kawasaki Disease is a self-limiting acute vasculitis with a specific predilection for the coronary arteries, which mainly affects children under five years of age^(2,30). The diagnosis is based on the presence of persistent fever lasting five days or more, associated with exanthema, lymphadenopathy, conjunctival hyperemia and alterations in the mucosa and extremities⁽³¹⁾.

When all the diagnostic criteria for the clinical picture of the disease cannot be met, some patients are diagnosed as having atypical or incomplete KD. In these cases, the disease is characterized when patients have persistent fever together with two or three diagnostic criteria for classic KD. Therefore, laboratory evaluation and echocardiography are recommended to assess the existence of coronary alterations so that the diagnosis of incomplete KD can be established^(32,33). In contrast to KD, there is the COVID-19 associated multisystem inflammatory syndrome, which, in turn, affects older children⁽²⁵⁻³⁰⁾. A pilot study of eight children developed in the United Kingdom showed they had persistent high fever (38–40°C), rashes of varied presentations, non-purulent conjunctivitis, edema of the hands and feet, severe abdominal pain, vomiting and diarrhea, symptoms suggestive of KD⁽³⁴⁾.

These findings are corroborated by a study conducted in the United States, in which an 11-year-old girl presented a condition of lack of appetite, leg pain, high and persistent fever, skin rash on the trunk and palms and generalized abdominal pain⁽²⁵⁾.

After the warning from the United Kingdom, other countries such as Spain, France and the United States began to identify the occurrence of cases of multisystem inflammatory syndrome in children and adolescents, probably associated to COVID-19. In the United States, more than 100 children hospitalized due to clinical manifestations and laboratory alterations compatible with complete Kawasaki syndrome, incomplete Kawasaki syndrome, and/or shock have been described. All of them had fever, more than half had rash, abdominal pain and diarrhea, and respiratory manifestations were rarely evidenced⁽³⁵⁻³⁷⁾.

It is known that SARS-CoV-2 replicates in respiratory and intestinal epithelial cells, resulting in tissue damage and excessive recruitment of innate and adaptive immune cells, which permeates a dysregulated hyperinflammatory response. Thus, cardiovascular symptoms should be observed given the similar manifestations to those of KD^(9,28,38), as well as skin

rash, diarrhea, vomiting and severe abdominal pain^(26,30). It is noteworthy that gastrointestinal symptoms are not characteristic of KD, which can facilitate the diagnosis of the disease.

Thus, it is possible to observe that the reason for children having a lower number of cases is that they remain at home for longer, making them less likely to contract the virus^(19,39,40) and also because they have less indications to undergo SARS-CoV-2 testing, since most of the time, they present mild symptoms^(6,40,41).

Since this is a new disease, few studies have been developed so far in comparison with other themes or pathologies. Thus, we decided to include “case study” works given the relevance of their results to elucidate the research question.

CONCLUSION

Most children were infected by their parents or close relatives and the clinical manifestations presented by the child population predominantly fit the mild or moderate forms of COVID-19, with a quick recovery. The main clinical manifestations presented by children infected with SARS-CoV-2 were fever, respiratory signs such as cough and dyspnea, gastrointestinal signs such as vomiting and diarrhea, and more recently, symptoms similar to KD, which was called COVID-19 associated multisystem inflammatory syndrome. However, health professionals must be alert to recognize these cases to enable appropriate and timely management during health care.

Although children are not the main focus of disease prevention, they are being directly affected by disease control measures through the closing of schools and reduced access to public spaces. Therefore, it is up to health professionals, especially the nursing staff by their important role of health educators, to guide parents on how to overcome this period of isolation with suggestions of activities for children, in addition to reinforcing guidelines and measures on how to prevent the infection with the virus.

It is noteworthy that there are still many doubts about the new coronavirus and that research on COVID-19 in the pediatric population is still scarce, requiring further studies to clarify the existing doubts. In addition, available data on the severity of COVID-19 in children with comorbidities are incipient, which limits the possibility of checking conditions at risk for further complications.

REFERENCES

1. Park JY, Han MS, Park KU, Kim JY, Choi EH. First Pediatric Case of Coronavirus Disease 2019 in Korea. *J Korean Med Sci* [Internet]. 2020 [cited 2020 May 3];35(11):e124. Available from: <https://doi.org/10.3346/jkms.2020.35.e124>.

2. Verdoni L, Mazza A, Gervasoni A, Martelli L, Ruggeri M, Ciuffreda M, et al. An outbreak of severe Kawasaki-like disease at the Italian epicentre of the SARS-CoV-2 epidemic: an observational cohort study. *Lancet* [Internet]. 2020 [cited 2020 May 13];395(10239):1771–8. Available from: [https://doi.org/10.1016/S0140-6736\(20\)31103-X](https://doi.org/10.1016/S0140-6736(20)31103-X).
3. Horton R. Offline: COVID-19 is not a pandemic. *Lancet* [Internet]. 2020 [cited 2020 Nov. 18];396(10255):874. Available from: [https://doi.org/10.1016/S0140-6736\(20\)32000-6](https://doi.org/10.1016/S0140-6736(20)32000-6).
4. Organização Pan-Americana de Saúde. Folha informativa sobre COVID-19. [Internet]. 2020 [cited 2020 Sept. 27]. Available from: <https://www.paho.org/pt/covid19>.
5. Brasil. Ministério da Saúde (BR). Painel coronavírus [Internet]. 2020 [cited 2020 Sept. 27]. Available from: <https://covid.saude.gov.br/>.
6. Vilelas JMS. The new coronavirus and the risk to children's health. *Rev Lat-Am Enfermagem* [Internet]. 2020 [cited 2020 May 3];28:e3320. Available from: <http://dx.doi.org/10.1590/1518-8345.0000.3320>.
7. Brasil. Ministério da Saúde (BR). Fluxo de Manejo Clínico Pediátrico na Atenção Especializada [Internet]. 2020 [cited 2020 May 3]. Available from: <https://www.saude.ms.gov.br/wp-content/uploads/2020/03/Fluxo-de-manejo-clinico-pedi-trico.pdf>.
8. Mahase E. Covid-19: concerns grow over inflammatory syndrome emerging in children. *BMJ* [Internet]. 2020 [cited 2020 May 8];369:m1710. Available from: <https://doi.org/10.1136/bmj.m1710>.
9. Li Y, Guo F, Cao Y, Li L, Guo Y. Insight into COVID-2019 for pediatricians. *Pediatr Pulmonol* [Internet]. 2020 [cited 2020 May 8];55(5):E1–E4. Available from: <https://doi.org/10.1002/ppul.24734>.
10. Souza MT, Silva MD, Carvalho R. Integrative review: what is it? How to do it? *Einstein* [Internet]. 2010 [cited 2020 June 3];8(1):102–6. Available from: <http://dx.doi.org/10.1590/s1679-45082010rw1134>.
11. Moher D, Liberati A, Tetzlaff J, Altman DG. Preferred Reporting Items for Systematic Reviews and Meta-Analyses: The PRISMA Statement. *PLoS Med*. [Internet]. 2009 [cited 2020 June 3];6(7):e1000097. Available from: <https://www.ncbi.nlm.nih.gov/pmc/articles/PMC2707599/>.
12. Brasil. Ministério da Saúde (BR). Estatuto da Criança e do Adolescente. 3. ed. Brasília, DF: Editora do Ministério da Saúde [Internet]. 2008. [cited 2020 Nov 16]. Available from: <http://bvsmms.saude.gov.br/bvs/publicacoes/estatuto-crianca-adolescente-3ed.pdf>.
13. Xu Y, Li X, Zhu B, Liang H, Fang C, Gong Y, et al. Characteristics of pediatric SARS-CoV-2 infection and potential evidence for persistent fecal viral shedding. *Nat Med* [Internet]. 2020 [cited 2020 June 4];26:502–55. Available from: <https://doi.org/10.1038/s41591-020-0817-4>.
14. Soltani J, Sedighi I, Shalchi Z, Sami G, Moradveisi B, Nahidi S. Pediatric coronavirus disease 2019 (COVID-19): An insight from west of Iran. *North Clin Istanb* [Internet]. 2020 [cited 2020 June 17];7(3):284–91. Available from: <https://doi.org/10.14744/nci.2020.90277>.
15. Sun D, Li H, Lu X, Xiao H, Ren J, Zhang F, et al. Clinical features of severe pediatric patients with coronavirus disease 2019 in Wuhan: a single center's observational study. *World J Pediatric* [Internet]. 2020 [cited 2020 June 5];16:251-9 Available from: <https://doi.org/10.1007/s12519-020-00354-4>.
16. Sociedade Brasileira de Pediatria (BR). Síndrome inflamatória multissistêmica em crianças e adolescentes provavelmente associada à COVID-19: uma apresentação aguda, grave e potencialmente fatal [Internet]. 2020 [cited 2020 Aug. 29]. Available from: https://www.sbp.com.br/fileadmin/user_upload/22532d-NA_Sindr_Inflamat_Multissistematica_associada_COVID19.pdf.
17. Souza TH, Nadal JA, Nogueira RJN, Pereira RM, Brandão MB. Clinical manifestations of children with COVID-19: A systematic review. *Pediatr Pulmonol* [Internet]. 2020 [cited 2020 Aug. 29];55(8):1892–9. Available from: <https://doi.org/10.1002/ppul.24885>.
18. Wang J, Wang D, Chen GC, Tao XW, Zeng LK. SARS-CoV-2 infection with gastrointestinal symptoms as the first manifestation in a neonate. *Chin J Contemp Pediatr* [Internet]. 2020 [cited 2020 June 28];22(3):211–4. Available from: <https://doi.org/10.7499/j.issn.1008-8830.2020.03.006>.
19. Lee PI, Hu YL, Chen PY, Huang YC, Hsueh PR. Are children less susceptible to COVID-19? *J Microbiol Immunol Infect* [Internet]. 2020 [cited 2020 June 20];53(3):371–2. Available from: <https://doi.org/10.1016/j.jmii.2020.02.011>.
20. Waltuch T, Gill P, Zinns LE, Whitney R, Tokarski J, Tsung JW, et al. Features of COVID-19 post-infectious cytokine release syndrome in children presenting to the emergency department. *Am J Emer Med* [Internet]. 2020 [cited 2020 June 28];38(10):2246.e3–2246.e6. Available from: <https://doi.org/10.1016/j.ajem.2020.05.058>.
21. Zhang GX, Zhang AM, Huang L, Cheng LY, Liu ZX, Peng XL, et al. Twin girls infected with SARS-CoV-2. *Chin J Contemp Pediatr* [Internet]. 2020 [cited 2020 June 20];22(3):221-5. Available from: <https://doi.org/10.7499/j.issn.1008-8830.2020.03.008>.

22. Cao Q, Chen YC, Chen CL, Chiu CH. SARS-CoV-2 infection in children: Transmission dynamics and clinical characteristics. *J Formos Med Assoc* [Internet]. 2020 [cited 2020 June 20];119(3):670–3. <https://doi.org/10.1016/j.jfma.2020.02.009>.
23. Su L, Ma X, Yu H, Zhang Z, Bian P, Han Y, et al. The different clinical characteristics of corona virus disease cases between children and their families in China – the character of children with COVID-19. *Emerg Microbes Infect* [Internet]. 2020 [cited 2020 June 17];9(1):707–13. Available from: <https://doi.org/10.1080/22221751.2020.1744483>.
24. Pain CE, Felsenstein S, Cleary G, Mayell S, Conrad K, Harave S, et al. Novel paediatric presentation of COVID-19 with ARDS and cytokine storm syndrome without respiratory symptoms. *Lancet Rheumatol* [Internet]. 2020 [cited 2020 July 10];2(7):E376–E9. Available from: [https://doi.org/10.1016/S2665-9913\(20\)30137-5](https://doi.org/10.1016/S2665-9913(20)30137-5).
25. Greene AG, Saleh M, Roseman E, Sinert R. Toxic shock-like syndrome and COVID-19: multisystem inflammatory syndrome in children (MIS-C). *Am J Emerg Med* [Internet]. 2020 [cited 2020 July 12];38(11):2492.e5–2492.e6. Available from: <https://doi.org/10.1016/j.ajem.2020.05.117>.
26. Blondiaux E, Parisot P, Redheuil A, Tzaroukian L, Levy Y, Sileo C, et al. Cardiac MRI in Children with Multisystem Inflammatory Syndrome with COVID-19. *Radiol* [Internet]. 2020 [cited 2020 July 17];297(3):e283–e288. Available from: <https://doi.org/10.1148/radiol.2020202288>.
27. Royal College of Obstetricians and Gynaecologists. Coronavirus (COVID-19) Infection in Pregnancy. Information for healthcare professionals [Internet]. 2020 [cited 2020 May 4]. Available from: <http://www.e-lactancia.org/media/papers/2020-04-03-coronavirus-covid-19-infection-in-pregnancy.pdf>.
28. Kaushik S, Aydin SI, Derespina KR, Bansal PB, Kowalsky S, Trachtman R, et al. Multisystem Inflammatory Syndrome in Children Associated with Severe Acute Respiratory Syndrome Coronavirus 2 Infection (MIS-C): A Multi-institutional Study from New York City. *J Pediatr* [Internet]. 2020 [cited 2020 July 17];224:24–9. Available from: <https://doi.org/10.1016/j.jpeds.2020.06.045>.
29. Chang LY, Lu CY, Shao PL, Lee PI, Lin MT, Fan TY, et al. Viral infections associated with Kawasaki disease. *J Formos Med Assoc* [Internet]. 2014 [cited 2020 Aug. 30];113(3):148–54. Available from: <https://doi.org/10.1016/j.jfma.2013.12.008>.
30. Papa A, Salzano AM, Di Dato MT, Varrassi G. Images in Practice: Painful Cutaneous Vasculitis in a SARS-Cov-2 IgG-Positive Child. *Pain Ther* [Internet]. 2020 [cited 2020 July 12]. Available from: <https://doi.org/10.1007/s40122-020-00174-4>.
31. Newburger JW, Takahashi M, Gerber MA, Gewitz MH, Tani LY, Burns JC, et al. Diagnosis, treatment, and long-term management of Kawasaki Disease: a statement for health professionals from the committee on rheumatic fever, endocarditis and Kawasaki Disease, council on cardiovascular disease in the young, american heart association. *Circulation* [Internet]. 2004 [cited 2020 Aug. 30];110(17):2747–71. Available from: <https://doi.org/10.1161/01.CIR.0000145143.19711.78>.
32. Rodrigues M, Oliveira JC, Carvalho F, Silva H, Moreira C, Granja S, et al. Doença de Kawasaki e complicações cardiovasculares em pediatria. *NEC* [Internet]. 2018 [cited 2020 Aug. 30];27(1):54–8. Available from: <http://www.scielo.mec.pt/pdf/nas/v27n1/v27n1a10.pdf>.
33. Castro PA, Urbano LMF, Costa IMC. Doença de Kawasaki. *An Bras Dermatol* [Internet]. 2009 [cited 2020 Aug. 30];84(4):317–29. Available from: <https://doi.org/10.1590/S0365-05962009000400002>.
34. Riphagen S, Gomez X, Gonzalez-Martinez C, Wilkinson N, Theocharis P. Hyperinflammatory shock in children during COVID-19 pandemic. *Lancet* [Internet]. 2020 [cited 2020 July 26];395(10237):1607–08. Available from: [https://doi.org/10.1016/S0140-6736\(20\)31094-1](https://doi.org/10.1016/S0140-6736(20)31094-1).
35. New York City Health Department. Childhood Inflammatory Disease Related to COVID-19 [Internet]. 2020 [cited 2020 Aug. 29]. Available from: <https://coronavirus.health.ny.gov/childhood-inflammatory-disease-related-covid-19>.
36. New York City Health Department. 2020 Health Alert #13: Pediatric Multi-System Inflammatory Syndrome Potentially Associated with COVID-19 [Internet]. 2020 [cited 2020 Aug. 29]. Available from: <https://www1.nyc.gov/assets/doh/downloads/pdf/han/alert/2020/covid-19-pediatric-multi-system-inflammatory-syndrome.pdf>.
37. Ramcharan T, Nolan O, Lai CY, Prabhu N, Krishnamurthy R, Ritcher AG, et al. Paediatric Inflammatory Multisystem Syndrome: Temporally Associated with SARS-CoV-2 (PIMS-TS): Cardiac Features, Management and Short-Term Outcomes at a UK Tertiary Paediatric Hospital. *Pediatr Cardiol* [Internet]. 2020 [cited 2020 July 29];41:1391–1401. Available from: <https://doi.org/10.1007/s00246-020-02391-2>.
38. Chiu JS, Lahoud-Rahme M, Schaffer D, Cohen A, Samuels-Kalow M. Kawasaki Disease Features and Myocarditis in a Patient with COVID-19. *Pediatr Cardiol* [Internet]. 2020 [cited 2020 July 10]; 41: 1526–8. Available from: <https://doi.org/10.1007/s00246-020-02393-0>.

39. Ji LN, Chao S, Wang YJ, Li XJ, Mu XD, Lin MG, et al. Clinical features of pediatric patients with COVID-19: a report of two family cluster cases. *World J Pediatr* [Internet]. 2020 [cited 2020 July 26];16:267–70. Available from: <https://doi.org/10.1007/s12519-020-00356-2>.
40. Qiu H, Wu J, Hong L, Luo Y, Song Q, Chen D. Clinical and epidemiological features of 36 children with coronavirus disease 2019 (COVID-19) in Zhejiang, China: an observational cohort study. *Lancet Infect Dis* [Internet]. 2020 [cited 2020 July 29];20(6):689–96. Available from: [https://doi.org/10.1016/S1473-3099\(20\)30198-5](https://doi.org/10.1016/S1473-3099(20)30198-5).
41. Wei L, Huaqian C, Kunwei L, Fang Y, Li S. Chest computed tomography in children with COVID-19 respiratory infection. *Pediatr Radiol* [Internet]. 2020 [cited 2020 July 29];50:796–99. Available from: <https://doi.org/10.1007/s00247-020-04656-7>.

